



# Associations between Serial Intravitreal Injections and Dry Eye

Agni Malmin, MD,<sup>1,2</sup> Vilde M. Thomseth, MD,<sup>1,3</sup> Per T. Førland, MD,<sup>1</sup> Ayyad Z. Khan, MD, PhD,<sup>4</sup> Hanne B. Hetland, MSc,<sup>5</sup> Xiangjun Chen, MD, PhD,<sup>4,6,7</sup> Inga-Britt K. Haugen, PhD,<sup>8</sup> Tor P. Utheim, MD, PhD,<sup>1,2,4,6,7</sup> Vegard A. Forsaa, MD, PhD<sup>1,3</sup>

**Purpose:** To investigate the effects of serial intravitreal injections (IVIs) on the ocular surface and meibomian glands (MGs) in patients treated with anti-vascular endothelial growth factor (anti-VEGF) for neovascular age-related macular degeneration (nAMD).

**Design:** Retrospective, controlled, observational study.

**Participants:** Patients with nAMD receiving unilateral IVIs with anti-VEGF agents. The fellow eye was used as control.

**Methods:** Tear film and ocular surface examinations were performed on a single occasion at a minimum of 4 weeks after IVI. A pre-IVI asepsis protocol with povidone-iodine (PVP-I) was applied.

**Main Outcome Measures:** Upper and lower MG loss, tear meniscus height (TMH), bulbar redness (BR) score, noninvasive tear break-up time (NIBUT), tear film osmolarity (TOsm), Schirmer test, corneal staining, fluorescein tear film break-up time (TBUT), meibomian gland expressibility (ME), and meibum quality.

**Results:** Ninety patients with a mean age of 77.5 years (standard deviation [SD], 8.4; range 54–95) were included. The median number of IVIs in treated eyes was 19.5 (range, 2–132). Mean MG loss in the upper eyelid was 19.1% (SD, 11.3) in treated eyes and 25.5% (SD, 14.6) in untreated fellow eyes ( $P = 0.001$ ). For the lower eyelid, median MG loss was 17.4% (interquartile range [IQR], 9.4–29.9) in treated eyes and 24.5% (IQR, 14.2–35.2) in fellow eyes ( $P < 0.001$ ). Mean BR was 1.32 (SD, 0.46) in treated eyes versus 1.44 (SD, 0.45) in fellow eyes ( $P = 0.017$ ). Median TMH was 0.36 mm (IQR, 0.28–0.52) in treated eyes and 0.32 mm (IQR, 0.24–0.49) in fellow eyes ( $P = 0.02$ ). There were no differences between treated and fellow eyes regarding NIBUT, TOsm, Schirmer test, corneal staining, fluorescein TBUT, ME, or meibum quality.

**Conclusions:** Repeated IVIs with anti-VEGF with preoperative PVP-I application was associated with reduced MG loss, increased tear volume, and reduced signs of inflammation compared with fellow nontreated eyes in patients with nAMD. This regimen may thus have a beneficial effect on the ocular surface.

**Financial Disclosure(s):** Proprietary or commercial disclosure may be found after the references. *Ophthalmology* 2023;130:509-515 © 2023 by the American Academy of Ophthalmology. This is an open access article under the CC BY license (<http://creativecommons.org/licenses/by/4.0/>).



Supplemental material available at [www.aaojournal.org](http://www.aaojournal.org).

The introduction of anti-vascular endothelial growth factor (anti-VEGF) has led to a therapeutic revolution for patients with neovascular age-related macular degeneration (nAMD). Over the past 15 years, indications for intravitreal injections (IVIs) with anti-VEGF have expanded rapidly, rendering IVI the most common intraocular procedure worldwide.<sup>1,2</sup> The effects on visual acuity and drug tolerance are excellent, but due to the natural course of macular diseases, anti-VEGF treatment must be repeated iteratively for months to years.<sup>3,4</sup> Although complications related to the procedure including sterile and infectious endophthalmitis have been widely reported, studies on long-term ocular surface effects of repeated injections are scarce.<sup>5-7</sup> Considering the high frequency and repetitive nature of the procedure, awareness of potential surface effects is warranted. Two additional issues further emphasize the importance of enhanced

knowledge on this topic. First, it is well known that preinjection antisepsis of the ocular surface with povidone-iodine (PVP-I) has a toxic effect on the corneal epithelium,<sup>8-10</sup> and second, patients with nAMD are already predisposed to dry eye disease (DED) due to their age and overall ocular health. The aim of the current study was to investigate the effect of serial IVIs on the ocular surface and meibomian glands (MGs) in patients with nAMD treated with anti-VEGF.

## Methods

Patients with nAMD receiving unilateral IVI at the Department of Ophthalmology, Stavanger University Hospital were recruited to participate in the study. Inclusion criteria were at least 2 previous IVIs in 1 eye, ongoing treatment intervals between 4 and 14 weeks,

and at least a 4-week interval between the last IVI and ocular surface assessments. Exclusion criteria were eyelid disease including ectropion, entropion, trichiasis, ptosis, and eyelid movement disorder caused by facial paralysis or use of ocular medications, except artificial tear lubricants. The number of previous IVIs were obtained from the patients' electronic records.

Patients received standard preparation for IVI with topical anesthesia: 1 drop of unpreserved tetracaine hydrochloride 1% ophthalmic solution (Minims, Bausch & Lomb, U.K. Inc.) followed by 1 drop of PVP-I 5% ophthalmic solution (Betadine; Alcon) applied to the ocular surface. The eye margin, lashes, and periorcular skin were cleaned with PVP-I 5%. After introduction of an eye speculum, PVP-I was again applied to the ocular surface before the IVI was administered. No antiseptic washout with saline irrigation was performed postinjection, and no postinjection topical treatment, such as use of antibiotics or ocular lubricants, was routinely applied or advised. The treat-and-extend protocol was used.<sup>11</sup>

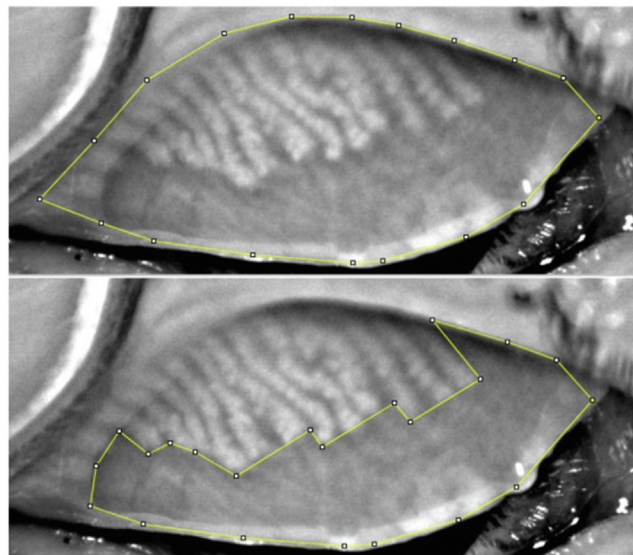
The study was approved by the Data Protection Officer at Stavanger University Hospital and the Regional Committee for Medical and Health Research Ethics (REK-ID 2019/832c) and was performed in accordance with the tenets of the Declaration of Helsinki. The study was conducted based on oral and written consent from the patients, and was registered at [ClinicalTrials.gov](https://www.clinicaltrials.gov) (identifier, NCT04458012).

## Clinical Measures

Ocular surface assessments were performed from least to most invasive to minimize the impact on subsequent measurements: Tear meniscus height (TMH), noninvasive tear film break-up time (NIBUT), and bulbar redness (BR) score were measured with the Keratograph 5M (Oculus Optikgeräte GmbH). Bulbar redness is an automated hyperemia measure on a 0- to 4-point scale. The TMH was measured inferior to the pupil center over the inferior eyelid margin. To evaluate NIBUT, patients were instructed to blink twice before refraining from blinking for as long as possible for a maximum of 24 seconds, and disruption of the tear film was automatically detected by the device. Tear film osmolarity (TOsm) was measured using the I-PEN Osmolarity System (I-MED Pharma Inc.). The Schirmer test was performed without anesthesia using sterile strips, following standard protocol.<sup>12</sup> Corneal staining was assessed using a biomicroscope with cobalt filtered light. A small drop of fluorescein sodium 2% solution was instilled with a glass rod to the inferior tarsus, and fluorescein staining of the cornea was evaluated according to the Oxford grading scheme ranging from 0 to 5.<sup>13</sup> Fluorescein tear film break-up time (TBUT) was recorded as the time interval between a complete blink and the first emergence of a dry spot in the precorneal tear film. Meibomian gland function in the lower lid was evaluated by applying moderate pressure on the lower lid margin using a cotton swab and viewed through biomicroscopy. Meibomian gland expressibility (ME) was evaluated on the basis of the number of expressible MGs among the central 5 glands using a 4-point score (0: 5 glands expressible; 1: 3–4 glands expressible; 2: 1–2 glands expressible; 3: 0 glands expressible). Meibum quality of each gland was assessed according to a 4-point score (0: clear; 1: cloudy; 2: granular; 3: toothpaste), and a sum and average score for the 8 central glands were calculated (sum score range: 0–24). Meibography was performed with the Keratograph 5M, and MG loss was determined using ImageJ software (Fig 1). The MG atrophy rate was calculated as  $(\text{AreaDropout}/\text{AreaTarsal plate} \times 100\%)$ . The evaluators were masked with respect to the eye receiving IVI.

## Statistical Analysis

Statistical analysis was conducted using SPSS 16.0.0 (SPSS Inc.). Boxplots was made using R Studio (R 4.1.2) and R packages



**Figure 1.** ImageJ-assisted meibomian gland (MG) atrophy analysis. The upper and lower photographs show gland and dropout areas, respectively.

ggplot2 and ggpubr. Descriptive data were reported as the mean  $\pm$  standard deviation (SD). Quantitative and non-normal distributed variables were described using the median and interquartile range (IQR). Differences were tested for normality distribution using the Shapiro–Wilk test. For normal distributed data, paired-sample *t* test was used to detect differences between treated and untreated eyes. For the non-normal distributed data, the Wilcoxon signed-rank test was used. Pearson and Spearman correlations were used to calculate the correlation between the number of IVIs received and the differences in ocular surface parameters between treated and fellow eyes. Two-sided  $P < 0.05$  was considered statistically significant in all analyses.

## Results

Ninety patients with a mean age of 77.5 years (SD, 8.4; range, 54–95) were included. Forty-seven patients were male (52%). The median number of IVIs in treated eyes was 19.5 (range, 2–132; IQR, 10.75–41.50). The median number of IVIs received during the last 12 months was 8 (range, 2–12). The median time interval between the most recent IVI was 4 weeks (range, 4–14). Thirteen patients (14%) reported using artificial tear lubricants regularly in both eyes. Table 1 summarizes the patient characteristics.

Meibography images of both lower eyelids were of sufficient quality for interpretation in 79 patients (88%) and for the upper lid in 33 patients (37%). Mean MG loss in the upper eyelid was 19.1% (SD, 11.3) in treated eyes and 25.5% (SD 14.6) in untreated fellow eyes ( $P = 0.001$ ) (Figs 2 and 3). For the lower eyelid, median MG loss was 17.4% (IQR, 9.4–29.9) in treated eyes and 24.5% (IQR, 14.2–35.2) in fellow eyes ( $P < 0.001$ ). Mean BR score was 1.32 (SD, 0.46) in treated eyes versus 1.44 (SD, 0.45) in fellow eyes ( $P = 0.017$ ). Median TMH was 0.36 (IQR, 0.28–0.52) mm in treated eyes and 0.32 (IQR, 0.24–0.49) mm in fellow eyes ( $P = 0.02$ ) (Fig S4, available at [www.aaojournal.org](http://www.aaojournal.org)). There were no differences between treated and fellow eyes regarding NIBUT, TOsm, Schirmer test, corneal staining, fluorescein TBUT, ME, or meibum quality (Table 2). An exploratory analysis was performed for testing the correlation between the number of IVIs and the differences in ocular surface parameters between treated and

Table 1. Patient Characteristics and Intravitreal Injection Numbers

<b>Patients</b>	Total, n (%)	90 (100)
	Female, n (%)	43 (47.8)
	Age	77.5 (SD, 8.4; range 54–95)
<b>Injections</b>	Number, total	19.5* (range, 2–132; IQR, 10.75–41.50)
	Number, last 12 months	8* (range, 2–12; IQR, 5–10)
	Time interval most recent injection (weeks)	4* (range, 4–14; IQR, 4–8)

IQR = interquartile range; SD = standard deviation.

\*Median.

fellow eyes. There were no significant correlations except the Schirmer test, which had a Pearson correlation coefficient of  $-0.21$  ( $P = 0.049$ , 95% confidence interval,  $-0.40$  to  $-0.001$ ) and a Spearman correlation coefficient of  $-0.24$  ( $P = 0.03$ ) (Table S3, available at [www.aaojournal.org](http://www.aaojournal.org)).

## Discussion

Contrary to our hypothesis that repeated IVIs increase the risk of DED, our study revealed healthier values of various dry eye parameters in eyes treated with IVI compared with the fellow untreated eyes. This raises the question: Can repeated IVIs have a positive effect on the ocular surface, and in such case, what are the mechanisms? The most conspicuous hypotheses are either the effect of repeated application of PVP-I, which has antibacterial properties that can be protective against ocular surface damage associated

with eyelid margin diseases, or the role of VEGF, which is a known mediator of inflammatory responses.

## Epitheliopathy

The most feared side effect of repeated anti-VEGF therapy is endophthalmitis. Before each IVI, an antiseptis procedure is systematically performed on the ocular surface to minimize the endophthalmitis risk.<sup>14</sup> The use of PVP-I as an antiseptic agent is attractive because of its broad antimicrobial spectrum, with activity against most Gram-positive and Gram-negative bacteria, including antibiotic- and antiseptic-resistant strains, fungi, amoebic cysts, spores, viruses, and protozoa.<sup>15</sup> The toxicity of PVP-I to the cornea has been shown in both human and rabbit models, causing severe damage to the corneal epithelium, depending on PVP-I concentration.<sup>8-10</sup> Contrary to previous studies, our study found no difference in corneal epitheliopathy between treated and fellow eyes.<sup>16,17</sup> This finding could be a result of dissipation of objective signs due to the longer time period from injection to examination, and we suspect that corneal staining could be higher immediately after the procedure.

Eyelid hygiene is part of the recommended treatment for chronic lid margin inflammation including meibomian gland dysfunction (MGD) and posterior blepharitis, and a possible mechanism for a beneficial effect on MGs and ocular surface health could be that repeated PVP-I application limits commensals through its potent antimicrobial properties. Alterations of the normal ocular microbial flora are found in blepharitis, and increased bacterial flora is shown to be associated with reduced goblet cell density.<sup>18</sup> A study by Jiang et al<sup>19</sup> on the microbiome of 140 eyes found that as

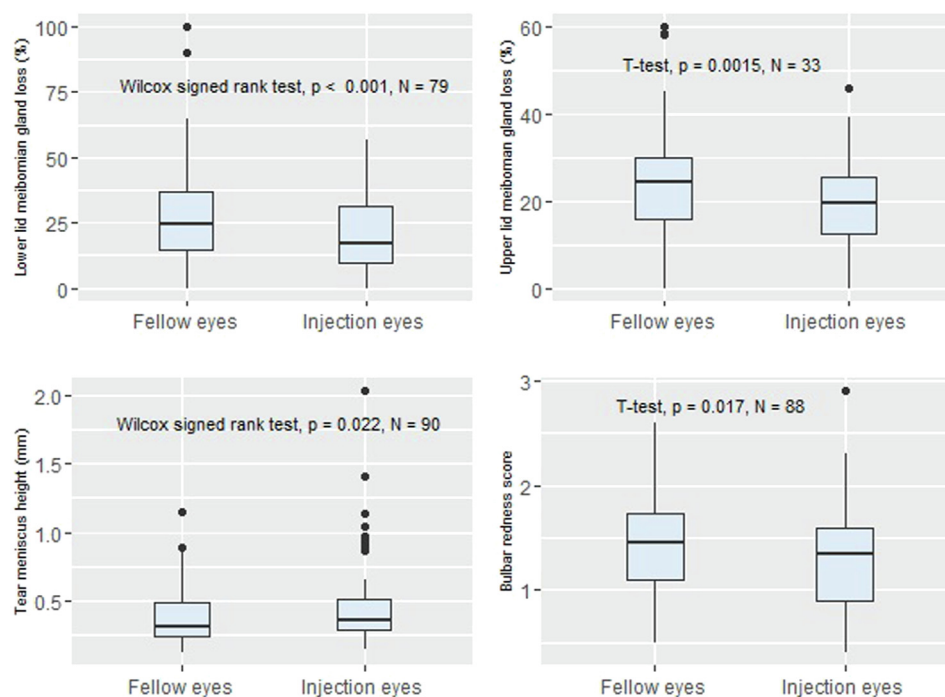
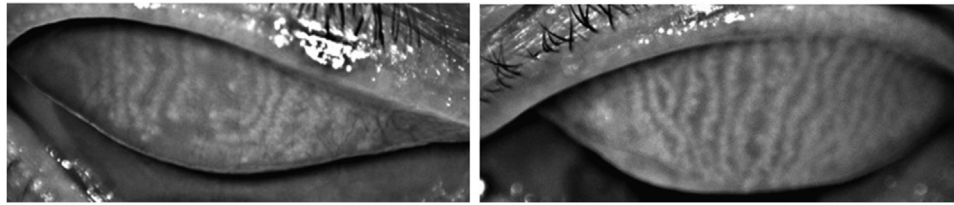


Figure 2. Differences between injection eyes and fellow eyes regarding upper and lower MG loss, tear meniscus height (TMH), and bulbar redness (BR) score. Boxes represent the median and interquartile range (IQR), error bars represent the range, and dots denote outliers.



**Figure 3.** Representative image of infrared meibography of the upper eyelids of a 72-year-old male patient who received 68 intravitreal injections (IVIs) in his left eye (right). Left image shows the fellow eye.

the severity of MGD increased, the composition of the microbiome became more complex, and the bacterial abundance increased.

### Anti-VEGF

Another issue to consider is whether anti-VEGF itself can have an impact on dry eye parameters. Vascular endothelial growth factor is the main factor regulating angiogenesis in multiple physiological processes and can act as a proinflammatory factor to stimulate the release of proinflammatory cytokines such as interleukin 6 and 8, and tumor necrosis factor- $\alpha$ .<sup>20</sup> Vascular endothelial growth factor levels are shown to be significantly increased in the tear fluid in patients with DED compared with healthy controls,<sup>21</sup> and Jiang et al<sup>22</sup> showed that injection of the anti-VEGF agent bevacizumab into the MG of patients with MGD improved dry eye parameters such as lid margin vascularity, conjunctival redness, and TBUT. Posterior lid-margin hyperemia with telangiectasia and increased vascularity is a pathological feature observed in more than 60% of patients with symptomatic MGD, and although the systemic absorption of anti-VEGF is low, we cannot disregard a potential effect on nearby tissues.<sup>23,24</sup> This could be a similar mechanism as in the case of intense pulsed light therapy, a novel treatment for MGD where long wavelength light is used to induce intravascular thrombosis of the small blood vessels surrounding the MG and telangiectasia of the eyelid margin, reducing the levels of proinflammatory mediators contributing to dry eye.<sup>25,26</sup>

### Meibomian Glands

Meibomian glands are sebaceous glands embedded in the tarsal plate of the upper and lower eyelids, from which meibum secretion constitutes the lipid layer of the pre-corneal tear film. Dysfunction of MG secretion is associated with dry eye symptoms, because the prevention of excessive evaporation of the aqueous layer and lubricant effect on the eyelids during blinking is impaired.<sup>27,28</sup> Aging is believed to be one of the most influential risk factors for MG loss.<sup>29</sup> Intriguingly, we found that eyes treated with IVI had less MG atrophy compared with fellow untreated eyes. This could be a result of persisting reduced inflammation in the eyelid aperture after the procedure, due to either PVP-I or the anti-VEGF agent, which could again lead to reduced atrophy of the MG.<sup>19,20</sup> Discordant data have been reported regarding ocular surface effects of anti-VEGF treatment. Polat et al<sup>30</sup> found significant MG loss in a study with 45 patients receiving IVI for age-related macular degeneration and diabetic macular edema. However, this was in comparison with 28 healthy controls, and the condition of diabetes might also have affected the MGs. Paired comparison using the fellow eye as a control as in our study is a powerful approach for comparing the effects of unilateral treatments on bilateral eye conditions like MG atrophy.<sup>31</sup> Also, the patients in the previous study received topical moxifloxacin 6 times per day for 10 days after each injection, which resulted in an average of more than 150 days of topical antibiotic applications. The patients in our study did not receive postoperative topical medication. A

Table 2. Differences in Ocular Surface Parameters between Treated and Fellow Eyes

	Treated Eyes	Fellow Eyes	95% CI Difference	n	P Value
BR score	1.32 (0.46)	1.44 (0.45)	0.12 [0.02–0.22]	88	<b>0.017</b>
Average NIBUT (sec)	13.6 (5.7)	13.5 (6.1)	–0.11 [–1.44 to 1.21]	81	0.87
Upper eyelid MG loss (%)	19.1 (11.3)	25.5 (14.6)	6.39 [2.65–10.13]	33	<b>0.001</b>
Lower eyelid MG loss (%)	17.4 (9.4–29.9)	24.5 (14.2–35.2)	7.35 [5.90–9.20]	79	<b>&lt;0.001</b>
Fluorescein TBUT (sec)	6 (4–12)	7 (4–12)	1.0 [0.0–2.0]	85	0.92
First NIBUT (sec)	6.3 (3.8–14.8)	6.3 (3.3–11.6)	3.25 [1.72–4.97]	81	0.63
TMH (mm)	0.36 (0.28–0.52)	0.32 (0.24–0.49)	0.08 [0.03–0.19]	90	<b>0.02</b>
Corneal staining (Oxford score)	0 (0–1)	0 (0–1)	0.00 [0.00–0.00]	88	0.69
Osmolarity (mOsm/l)	327 (303–334)	319 (303–327)	15.5 [10.0–22.0]	69	0.11
Schirmer test (mm)	9 (5–16)	7 (5–16)	2.0 [1.0–3.0]	87	0.42
ME	0 (0–1)	0 (0–1)	0.00 [0.00–0.00]	82	0.32
Meibum quality	0 (0–2)	0 (0–2)	0.00 [0.00–0.00]	80	0.30

BR = bulbar redness; CI = confidence interval; ME = meibomian gland expressibility; MG = meibomian gland; NIBUT = noninvasive tear film break-up time; TBUT = tear film break-up time; TMH = tear meniscus height.

Mean values with SDs and \*median values with interquartile range. Boldface indicates statistical significance.

study by Ulutas and Yener<sup>32</sup> on 49 patients receiving IVI for retinal vascular disorders showed no significant effect of IVI on any dry eye parameters. However, the participants in their study had received a mean number of only 4 injections and MGs were not evaluated.

## Tear Volume

The tear menisci act as a tear reservoir supplying fluid to the precorneal tear film, which becomes reformed with each eye blink. Tear meniscus height is linearly associated to the tear volume<sup>33</sup> and is a useful measure in DED.<sup>34</sup> We found an increased TMH in injected eyes compared with fellow noninjected eyes. This is in accordance with a study by Dohlman et al,<sup>16</sup> which evaluated signs and symptoms of ocular surface disease in 20 patients receiving serial IVIs. The study found that tear osmolarity paradoxically decreased as the number of injections per year increased. The authors proposed that the aggravating nature of PVP-I could stimulate the lacrimal-functional unit, thereby increasing tear volume. However, despite increased tear volume in the lid aperture, we did not find differences in TOsm between treated and untreated eyes in our study.

## Redness

Bulbar redness is a nonspecific ocular response due to vasodilatation of the conjunctival or anterior scleral blood vessels, and a prominent feature of ocular irritation.<sup>35</sup> Both MGD and DED are known to induce hyperemia.<sup>36</sup> Contrary to our expectations, we found that eyes treated with IVI had a lower redness score compared with untreated eyes. This finding suggests that injection eyes had a lower degree of inflammation compared with fellow eyes. Although not statistically significant, other tear film parameters such as NIBUT and Schirmer test also showed a tendency toward healthier values in treated eyes compared with fellow eyes.

Strengths of the present study are as follows: First, patients were their own controls, thus avoiding medical and environmental-related biases. Second, the high number of injections compared with other studies increase the likelihood of detecting secondary IVI effects. Third, we do not use

postinjection topical antibiotics or lubricants in our clinic. This way we avoid both the potential bias of ocular surface inflammation induced by preservatives in topical preparations and a possible improvement of ocular surface status by the use of lubricants.

## Study Limitations

There are some limitations of the present study. Meibomian gland dropout and tarsal areas were measured semi-automatically using ImageJ software. Although the semi-objective analysis of MG dropout is superior regarding intraobserver and interobserver agreement compared with the subjective meiboscore, the variance of image quality and the observer's subjective quantifications could lead to a limited repeatability of the measurements.<sup>37</sup> The low number of gradable images of MG in the upper eyelids could potentially introduce bias, because eyelids with pronounced blepharitis could be more difficult to evert. However, it is reasonable to assume to some degree similar changes in upper and lower eyelids, and despite the low number of images, the findings in the upper lid are equivalent to the findings in the lower lids. Regarding epithelial damage of the ocular surface, staining with lissamine green would have revealed possible epitheliopathy of the conjunctiva, but was not performed in this study. Another limitation is the retrospective and observational design of the study, which does not enable us to establish causality between IVI and dry eye parameters, merely to describe associations and generate hypotheses. With regard to statistics, the increase in familywise error rate across the reported statistical analyses was not controlled. Overall, we consider this research to be relatively preliminary, and we encourage replication.

## Conclusions

Our study raises the question of potential protective effects of repeated IVIs on the ocular surface. Further investigations with prospective studies are warranted to support our findings and explore the mechanisms involved.

## Footnotes and Disclosures

Originally received: August 18, 2022.

Final revision: November 25, 2022.

Accepted: January 17, 2023.

Available online: January 21, 2023. Manuscript no. OPHTHA-D-22-01493

<sup>1</sup> Department of Ophthalmology, Stavanger University Hospital, Stavanger, Norway.

<sup>2</sup> Department of Clinical Medicine, University of Bergen, Bergen, Norway.

<sup>3</sup> Department of Quality and Health Technology, University of Stavanger, Stavanger, Norway.

<sup>4</sup> Department of Medical Biochemistry, Oslo University Hospital, Oslo, Norway.

<sup>5</sup> Department of Research, Section of Biostatistics, Stavanger University Hospital, Stavanger, Norway.

<sup>6</sup> Department of Ophthalmology, Hospital of Southern Norway, Arendal, Norway.

<sup>7</sup> Department of Ophthalmology, Vestre Viken Hospital Trust, Drammen, Norway.

<sup>8</sup> Norwegian Association of the Blind and Partially Sighted, Oslo, Norway. Disclosure(s):

All authors have completed and submitted the ICMJE disclosures form.

The author(s) have made the following disclosure(s): T.P.U.: Co-founder and co-owner – The Norwegian Dry Eye Clinic and the Clinic of Eye Health, Oslo, Norway, which delivers talks for or receives financial support from ABIGO, Alcon, Allergan, AMWO, Bausch + Lomb, Bayer, European School for Advanced Studies in Ophthalmology, InnZ Medical, Medilens Nordic, Medistim, Novartis, Santen, Specsavers, ShirePharmaceuticals, Thea Laboratories; Global scientific advisory board – Novartis, Alcon; European Advisory Board – Shire Pharmaceuticals; Norwegian Global Ambassador – Tear Film and Ocular Surface Society; Board Member – International Ocular Surface Society; Consultant – Norwegian Association

for the Blind and Partially Sighted; Editor-in-Chief — *Ophthalmology*, an eye journal distributed to all eye doctors in the Nordic region since 1980.

The project was partly funded by the Norwegian Association of the Blind and Partially Sighted. The funding organization had no role in the design or conduct of this research.

Presented in part at: the Nordic Congress of Ophthalmology, June 9–11, 2022, Reykjavik, Iceland.

**HUMAN SUBJECTS:** Human subjects were included in this study. The human ethics committees at the Data Protection Officer at Stavanger University Hospital and the Regional Committee for Medical and Health Research Ethics (REK-ID 2019/832c) approved the study. All research adhered to the tenets of the Declaration of Helsinki. All participants provided informed consent.

No animal subjects were used in this study.

**Author Contributions:**

Conception and design: Malmin, Thomseth, Hetland, Haugen, Utheim, Forsaa

Data collection: Malmin, Thomseth, Forland, Khan, Hetland, Utheim, Forsaa

Analysis and interpretation: Malmin, Thomseth, Hetland, Chen, Haugen, Utheim, Forsaa

Obtained funding: N/A

Overall responsibility: Malmin, Thomseth, Forland, Khan, Hetland, Chen, Haugen, Utheim, Forsaa

**Abbreviations and Acronyms:**

**BR** = bulbar redness; **DED** = dry eye disease; **IQR** = interquartile range; **IVI** = intravitreal injection; **ME** = meibomian gland expressibility; **MG** = meibomian gland; **MGD** = meibomian gland dysfunction; **nAMD** = neovascular age-related macular degeneration; **NIBUT** = noninvasive tear break-up time; **PVP-I** = povidone-iodine; **SD** = standard deviation; **TBUT** = tear film break-up time; **TMH** = tear meniscus height; **TOsm** = tear film osmolarity; **VEGF** = vascular endothelial growth factor.

**Keywords:**

Anti-VEGF, Dry eye disease, Intravitreal injections, Meibomian glands, Povidone iodine.

**Correspondence:**

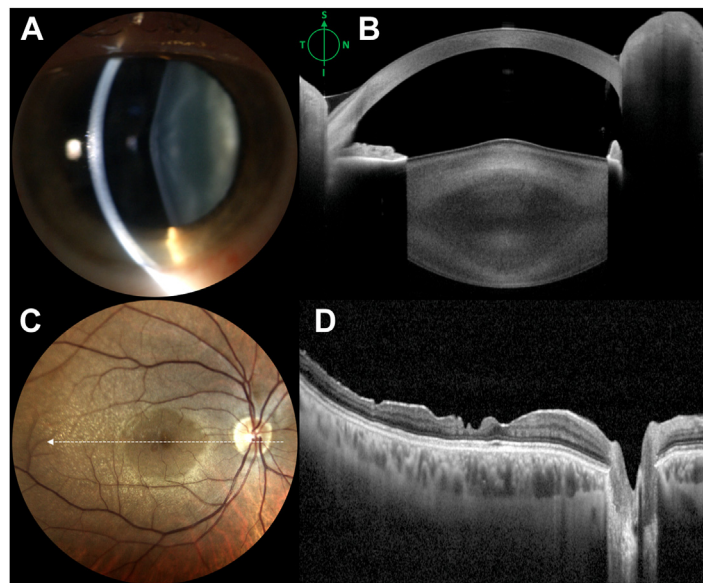
Agni Malmin, MD, Department of Ophthalmology, Stavanger University Hospital, PO Box 8100, N-4068 Stavanger, Norway. E-mail: [agni.malmin@sus.no](mailto:agni.malmin@sus.no).

## References

- McLaughlin MD, Hwang JC. Trends in vitreoretinal procedures for Medicare beneficiaries, 2000 to 2014. *Ophthalmology*. 2017;124:667–673.
- Chopra R, Preston GC, Keenan TDL, et al. Intravitreal injections: past trends and future projections within a UK tertiary hospital. *Eye*. 2021;36:1373–1378.
- Heier JS, Brown DM, Chong V, et al. Intravitreal aflibercept (VEGF trap-eye) in wet age-related macular degeneration. *Ophthalmology*. 2012;119:2537–2548.
- Martin DF, Maguire MG, Fine SL, et al. Ranibizumab and bevacizumab for treatment of neovascular age-related macular degeneration: two-year results. *Ophthalmology*. 2012;119:1388–1398.
- Rayess N, Rahimy E, Shah CP, et al. Incidence and clinical features of post-injection endophthalmitis according to diagnosis. *Br J Ophthalmol*. 2016;100:1058–1061.
- Baudin F, Benzenine E, Mariet AS, et al. Association of acute endophthalmitis with intravitreal injections of corticosteroids or anti-vascular growth factor agents in a nationwide study in France. *JAMA Ophthalmol*. 2018;136:1352–1358.
- Wickremasinghe SS, Michalova K, Gilhotra J, et al. Acute intraocular inflammation after intravitreal injections of bevacizumab for treatment of neovascular age-related macular degeneration. *Ophthalmology*. 2008;115:1911–1915.
- Ridder 3rd WH, Oquindo C, Dhamdhare K, Burke J. Effect of povidone iodine 5% on the cornea, vision, and subjective comfort. *Optom Vis Sci*. 2017;94:732–741.
- Kim S, Ahn Y, Lee Y, Kim H. Toxicity of povidone-iodine to the ocular surface of rabbits. *BMC Ophthalmol*. 2020;20:359.
- Mac Rae SM, Brown B, Edelhauser HF. The corneal toxicity of presurgical skin antiseptics. *Am J Ophthalmol*. 1984;97:221–232.
- Fung AE, Lalwani GA, Rosenfeld PJ, et al. An optical coherence tomography-guided, variable dosing regimen with intravitreal ranibizumab (Lucentis) for neovascular age-related macular degeneration. *Am J Ophthalmol*. 2007;143:566–583.
- Methodologies to diagnose and monitor dry eye disease. report of the Diagnostic Methodology Subcommittee of the International Dry Eye WorkShop (2007). *Ocul Surf*. 2007;5:108–152.
- Bron AJ, Evans VE, Smith JA. Grading of corneal and conjunctival staining in the context of other dry eye tests. *Cornea*. 2003;22:640–650.
- Shimada H, Hattori T, Mori R, et al. Minimizing the endophthalmitis rate following intravitreal injections using 0.25 % povidone-iodine irrigation and surgical mask. *Graefes Arch Clin Exp Ophthalmol*. 2013;251:1885–1890.
- Lachapelle J-M, Castel O, Casado AF, et al. Antiseptics in the era of bacterial resistance: a focus on povidone iodine. *Clin Pract*. 2013;10:579–592.
- Dohlman TH, Lertsuwanroj B, D'Amico DJ, et al. Evaluation of signs and symptoms of ocular surface disease after intravitreal injection. *Acta Ophthalmol*. 2019;97:e1154–e1156.
- Saedon H, Nosek J, Phillips J, et al. Ocular surface effects of repeated application of povidone iodine in patients receiving frequent intravitreal injections. *Cutan Ocul Toxicol*. 2017;36:343–346.
- Graham JE, Moore JE, Jiru X, et al. Ocular pathogen or commensal: a PCR-based study of surface bacterial flora in normal and dry eyes. *Invest Ophthalmol Vis Sci*. 2007;48:5616–5623.
- Jiang X, Deng A, Yang J, et al. Pathogens in the Meibomian gland and conjunctival sac: microbiome of normal subjects and patients with Meibomian gland dysfunction. *Infect Drug Resist*. 2018;11:1729–1740.
- Yoo SA, Kwok SK, Kim WU. Proinflammatory role of vascular endothelial growth factor in the pathogenesis of rheumatoid arthritis: prospects for therapeutic intervention. *Mediators Inflamm*. 2008;2008:129873.
- Roda M, Corazza I, Bacchi Reggiani ML, et al. Dry eye disease and tear cytokine levels—a meta-analysis. *Int J Mol Sci*. 2020;21:3111.
- Jiang X, Wang Y, Lv H, et al. Efficacy of intra-meibomian gland injection of the anti-VEGF agent bevacizumab for the treatment of meibomian gland dysfunction with lid-margin vascularity. *Drug Des Devel Ther*. 2018;12:1269–1279.
- Lin PY, Cheng CY, Hsu WM, et al. Association between symptoms and signs of dry eye among an elderly Chinese

- population in Taiwan: the Shihpai Eye Study. *Invest Ophthalmol Vis Sci.* 2005;46:1593–1598.
24. Avery RL, Castellarin AA, Steinle NC, et al. Systemic pharmacokinetics and pharmacodynamics of intravitreal aflibercept, bevacizumab, and ranibizumab. *Retina.* 2017;37:1847–1858.
  25. Angermeier MC. Treatment of facial vascular lesions with intense pulsed light. *J Cutan Laser Ther.* 1999;1:95–100.
  26. Liu R, Rong B, Tu P, et al. Analysis of cytokine levels in tears and clinical correlations after intense pulsed light treating meibomian gland dysfunction. *Am J Ophthalmol.* 2017;183:81–90.
  27. Nelson JD, Shimazaki J, Benitez-del-Castillo JM, et al. The international workshop on meibomian gland dysfunction: report of the definition and classification subcommittee. *Invest Ophthalmol Vis Sci.* 2011;52:1930–1937.
  28. Blackie CA, Korb DR, Knop E, et al. Nonobvious obstructive meibomian gland dysfunction. *Cornea.* 2010;29:1333–1345.
  29. Arita R, Itoh K, Inoue K, Amano S. Noncontact infrared meibography to document age-related changes of the meibomian glands in a normal population. *Ophthalmology.* 2008;115:911–915.
  30. Polat OA, Çetinkaya Z, Evereklioglu C, et al. Effect of repeated topical povidone-iodine and antibiotic applications on meibomian glands and ocular surface parameters in patients with repeated intravitreal injections. *Eye Contact Lens.* 2021;47:651–654.
  31. Murdoch IE, Morris SS, Cousens SN. People and eyes: statistical approaches in ophthalmology. *Br J Ophthalmol.* 1998;82:971–973.
  32. Ulutas HG, Yener NP. Effects of intravitreal injection on ocular surface and anterior segment parameters. *Beyoglu Eye J.* 2021;6:84–89.
  33. Yokoi N, Bron AJ, Tiffany JM, et al. Relationship between tear volume and tear meniscus curvature. *Arch Ophthalmol.* 2004;122:1265–1269.
  34. Yazdani M, Chen X, Tashbayev B, et al. Tear production levels and dry eye disease severity in a large Norwegian cohort. *Curr Eye Res.* 2018;43:1465–1470.
  35. Papas EB. Key factors in the subjective and objective assessment of conjunctival erythema. *Invest Ophthalmol Vis Sci.* 2000;41:687–691.
  36. Schulze MM, Ng A, Yang M, et al. Bulbar redness and dry eye disease: comparison of a validated subjective grading scale and an objective automated method. *Optom Vis Sci.* 2021;98:113–120.
  37. Pult H, Riede-Pult B. Comparison of subjective grading and objective assessment in meibography. *Cont Lens Anterior Eye.* 2013;36:22–27.

## Pictures & Perspectives



### Anterior Segment and Macular OCT in Alport Syndrome

The authors examined a 48-year-old White man with genetically confirmed diagnosis of X-linked Alport syndrome. His vision was 20/25 Snellen in both eyes, while anterior segment examination revealed bilateral anterior lenticonus (A). High-resolution swept-source anterior segment OCT (Anterior, Heidelberg Engineering) showed anterior bulging of the lens in greater detail (B). Fundus photography documented peri-macular dot-and-fleck retinopathy giving rise to the typical “lozenge-sign” (C, Eidon, Centervue) caused by the hyper-reflectivity and thickening of the internal limiting membrane. Widefield OCT revealed macular temporal thinning and irregular depletion of inner retinal layers with preservation of outer retina, which is known as “staircase-foveopathy” (D) (Magnified version of Fig A–D is available online at [www.aaojournal.org](http://www.aaojournal.org)).

CHIARA ZAFFALON, MD<sup>1,2</sup>  
FRANCESCO ROMANO, MD<sup>2</sup>  
ANNA PAOLA SALVETTI, MD<sup>2</sup>

<sup>1</sup>Ophthalmic Unit, Department of Neurosciences, Biomedicine and Movement Sciences, University of Verona, Verona, Italy; <sup>2</sup>Eye Clinic, Department of Biomedical and Clinical Science, Luigi Sacco Hospital, University of Milan, Milan, Italy