

REVIEW ARTICLE

Intense pulsed light treatment in meibomian gland dysfunction: Past, present, and future

Fredrik Fineide^{1,2,3,4} | Morten S. Magno^{4,5,6,7,8} | Ayyad Zartasht Khan⁴ |
Xiangjun Chen^{4,5,9,10} | Jelle Vehof^{6,11,12,13} | Tor P. Utheim^{1,3,4,5,8,9,10,13,14,15,16,17,18,19,20}

¹Department of Computer Science, Oslo Metropolitan University, Oslo, Norway

²SimulaMet, Oslo, Norway

³The Norwegian Dry Eye Clinic, Oslo, Norway

⁴Department of Medical Biochemistry, Oslo University Hospital, Oslo, Norway

⁵Department of Ophthalmology, Sørlandet Hospital Arendal, Arendal, Norway

⁶Department of Ophthalmology, University of Groningen, University Medical Center Groningen, Groningen, The Netherlands

⁷Institute of Clinical Medicine, Faculty of Medicine, University of Oslo, Oslo, Norway

⁸Department of Plastic and Reconstructive Surgery, Oslo University Hospital, Oslo, Norway

⁹Department of Ophthalmology, Drammen Hospital, Vestre Viken Trust, Drammen, Norway

¹⁰National Centre for Optics, Vision and Eye Care, Department of Optometry, Radiography and Lighting Design, Faculty of Health Sciences, University of South-Eastern Norway, Kongsberg, Norway

¹¹Department of Ophthalmology, Vestfold Hospital Trust, Tønsberg, Norway

¹²Department of Twin Research & Genetic Epidemiology, King's College London, St Thomas' Hospital, London, United Kingdom

¹³Department of Epidemiology, University of Groningen, University Medical Centre Groningen, Groningen, The Netherlands

¹⁴Department of Ophthalmology, Stavanger University Hospital, Stavanger, Norway

¹⁵Department of Clinical Medicine, Faculty of Medicine, University of Bergen, Bergen, Norway

¹⁶Department of Quality and Health Technology, The Faculty of Health Sciences, University of Stavanger, Stavanger, Norway

¹⁷Department of Ophthalmology, Oslo University Hospital, Oslo, Norway

¹⁸Department of Oral Biology, Faculty of Dentistry, University of Oslo, Oslo, Norway

¹⁹Department of Health and Nursing Science, The Faculty of Health and Sport Sciences, University of Agder, Grimstad, Norway

²⁰Department of Ophthalmology, Faculty of Life Course Sciences and Medicine, King's College London, London, UK

Correspondence

Fredrik Fineide, Department of Computer Science, Oslo Metropolitan University, Oslo, Norway.
Email: fre_fin@hotmail.com

Abstract

Dry eye disease is a highly prevalent condition, which can substantially impair quality of life, work productivity, and vision. It is considered an inflammatory disease and the most common cause is meibomian gland dysfunction. Despite many treatment alternatives being available, including artificial tears, warm compresses, antibiotics, and anti-inflammatory therapy, lasting treatment effects are rare. Over the last two decades, intense pulsed light therapy, after being well established in dermatology, has been gradually introduced to the field of ophthalmology to treat meibomian gland dysfunction. The purpose of the current article is to critically review the clinical studies assessing the use of intense pulsed light to treat meibomian gland dysfunction published to date. The vast majority of the included studies demonstrated improved symptoms and signs, although the degree of efficacy and its duration varied greatly depending on concomitant treatment, number of treatment sessions, and other factors. Several possible mechanisms of action concerning disease propagation and treatment efficacy are discussed. There is still a need for larger, randomised, longitudinal studies to define the most efficacious treatment regime and to predict which patients may benefit the most. More studies are needed on implementing biochemical analyses and machine learning algorithms. Such studies may prove beneficial in predicting treatment effects, defining optimal

This is an open access article under the terms of the [Creative Commons Attribution-NonCommercial](https://creativecommons.org/licenses/by-nc/4.0/) License, which permits use, distribution and reproduction in any medium, provided the original work is properly cited and is not used for commercial purposes.

© 2023 The Authors. *Acta Ophthalmologica* published by John Wiley & Sons Ltd on behalf of Acta Ophthalmologica Scandinavica Foundation.

treatment regimens, and furthering our understanding of the mechanisms of action.

KEYWORDS

dry eye disease, intense pulsed light, meibomian gland dysfunction, meibomian gland expression

1 | INTRODUCTION

1.1 | Dry eye disease

The tear film consists of an inner mucoaqueous layer and an outer lipid layer (Willcox et al., 2017; Figure 1). The mucin part of the inner mucoaqueous layer is largely produced by goblet cells on the epithelial surface, with the aqueous portion stemming from the lacrimal glands. The outer lipid layer is produced by the meibomian glands (MG).

Dry eye disease (DED) is one of the most common medical conditions, with a prevalence ranging from 5% to 50%, depending on geographical region, population studied and diagnostic criteria (Stapleton et al., 2017). It is a multifactorial disease that disrupts the tear film homeostasis (Craig et al., 2017). Generally, DED is divided into the non-mutually exclusive subgroups aqueous deficient and evaporative DED. Evaporative DED is the most common form, and meibomian gland dysfunction (MGD) is the leading cause of evaporative DED. Although signs and symptoms can arise at any time, prevalence is associated with female sex and advancing age (Nelson et al., 2017). Symptoms vary, ranging from mild discomfort through ocular fatigue, dryness and foreign body sensation to blurred vision and debilitating pain. The annual economic cost to the United States alone in terms of low productivity and leave

of absence due to DED was in 2014 estimated to amount to as much as \$55 billion (Uchino et al., 2014).

1.2 | Meibomian gland dysfunction

The MGs are located at regular intervals superficially in the tarsal plates of the eyelids (Knop et al., 2011) (Figure 2). The upper eyelid typically contains 25–40 separate glands while the lower eyelids usually have 20–30. The MGs of the lower eyelids are shorter and wider than the longer and slimmer found in the upper eyelids. The functional subunits of MGs are modified sebaceous cells referred to as meibocytes, which synthesise and secrete the oily meibum. The MGs end at the posterior lid margin, anterior to the mucocutaneous junction (Knop et al., 2011). Healthy meibum increases tear film stability, lowers surface tension, promotes even spreading of tears, reduces evaporation of the mucoaqueous layer and protects the ocular surface against foreign microorganisms and other external agents (Willcox et al., 2017). The international workshop on MGD defines it as ‘a chronic, diffuse abnormality of the meibomian glands, commonly characterised by terminal duct obstruction and/or qualitative/quantitative changes in the glandular secretion. This may result in alteration of the tear film, symptoms of eye irritation, clinically apparent inflammation,

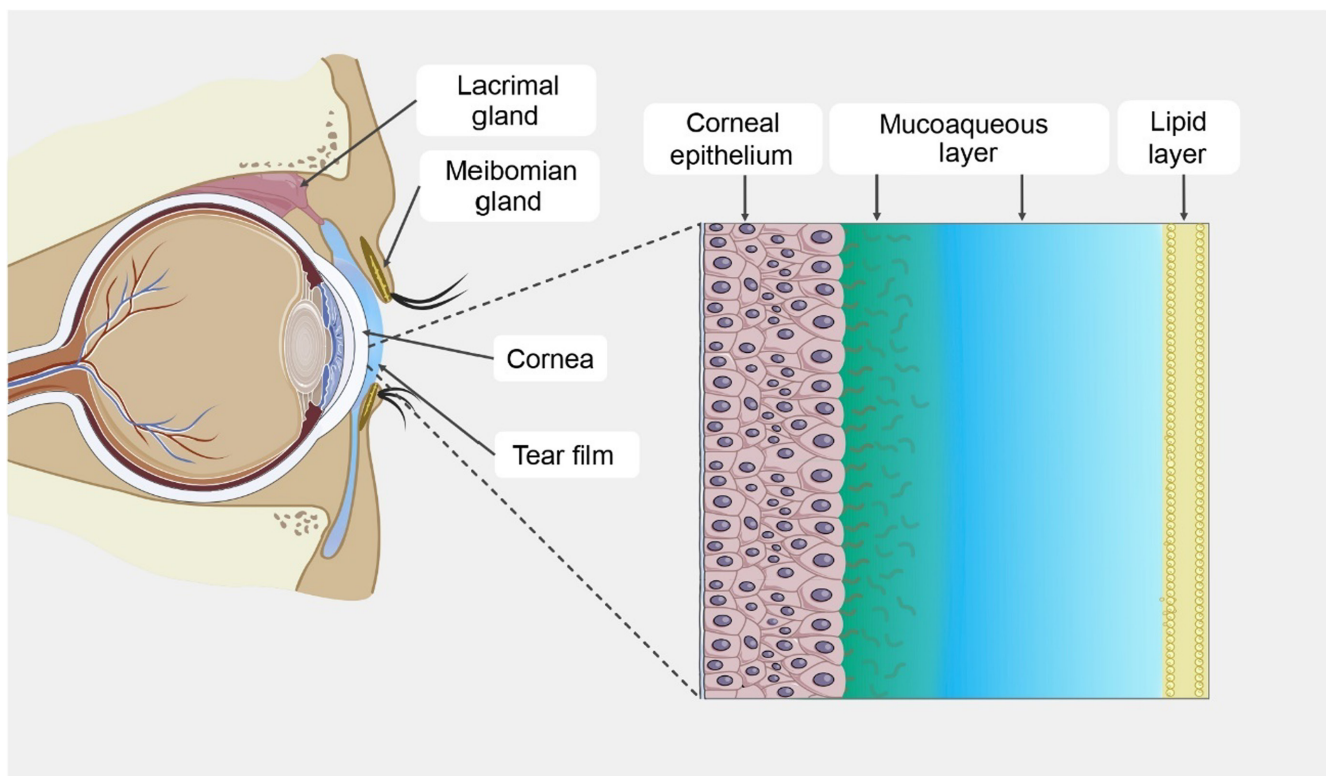


FIGURE 1 The structure of the tear film.

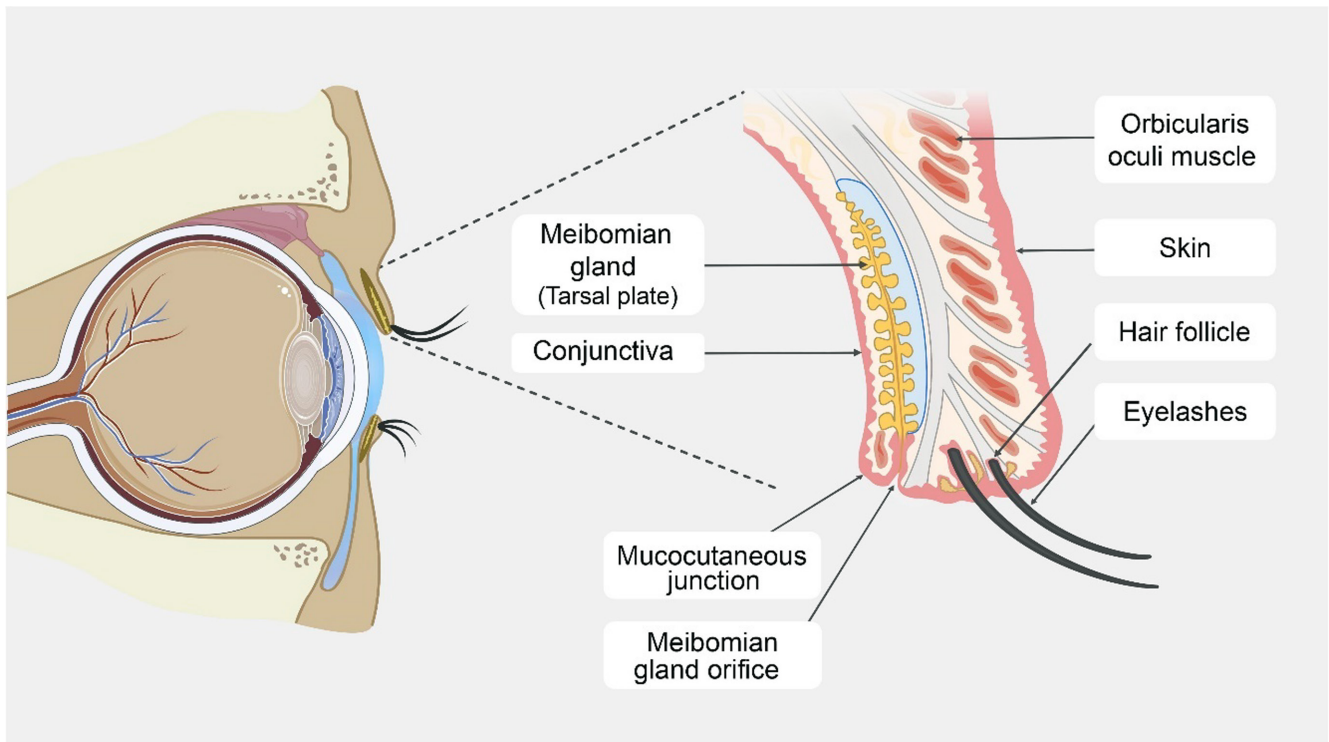


FIGURE 2 The human eyelid anatomy.

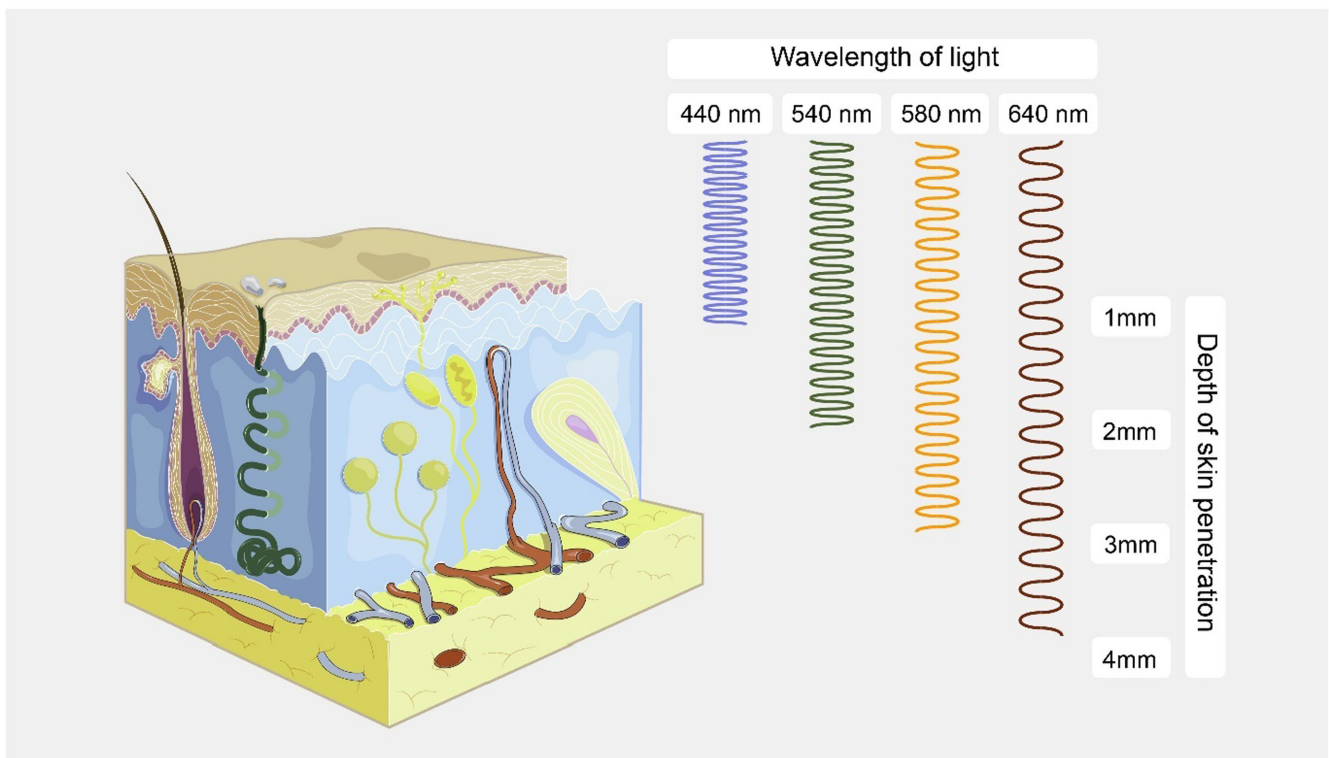


FIGURE 3 The penetration depth of different wavelengths.

and ocular surface disease' (Nelson et al., 2011). MGD can be further subdivided into hyposecretory or low-delivery and hypersecretory or high-delivery state. Hyposecretory MGD is believed to be the most common aetiology. It results from glandular obstruction: terminal duct obstruction, hyperkeratinisation of the MG ducts, or from primary hyposecretion. Hypersecretory MGD is associated with seborrheic dermatitis and other diseases such as rosacea and atopy (Nelson et al., 2011).

2 | INTENSE PULSED LIGHT

2.1 | Historical background

The application of laser or broad-band infrared light for thermocoagulation in treating port-wine stains and capillary hemangiomas was first described by Mühlbauer et al. (1976). Subsequently, Anderson and Parrish described selective photothermolysis on

TABLE 1 Summary of studies using IPL therapy for treating DED.

	Study (Author/year) country of origin	Purpose	Design	Number of subjects
<i>IPL as isolated treatment modality—Randomised studies</i>				
1.	Craig et al. (2015) New Zealand	Evaluate efficacy of IPL in treating MGD	Prospective, double-masked, placebo-controlled, paired-eye study	28; contralateral eye serving as control receiving placebo treatment
2.	Zhang et al. (2019) China	Compare efficacy in treating ocular demodicosis between IPL and tea tree oil	Prospective, randomised, single blind	40 total, 20 in each group
3.	Piyacorn et al. (2019) Thailand	Evaluate efficacy and safety of IPL therapy in patients with MGD	Prospective, randomised, double-masked, sham-controlled clinical trial	114 total; IPL: 57; sham treatment: 57
4.	Gao et al. (2019) China	To compare the anti-inflammatory effect of IPL versus tobramycin/dexamethasone and warm compresses	Prospective, randomised trial	82 total, 41 in each group
5.	Zarei-Ghanavati, Hassanzadeh, Azimi Khorasani, et al. (2021) Iran	Assess the efficacy of a novel five-flash IPL technique in combination with home-based therapy and to compare it with conventional home care alone in patients with MGD	Prospective, randomised controlled trial	100 total; IPL: 50; control: 50
6.	Song et al. (2021) China	Evaluate tear film lipid layer alteration and function following IPL in patients with EDE	Prospective, randomised, single masked, sham controlled	86 completed the study; IPL: 45; sham treatment: 41
7.	Yan and Wu (2021) China	Evaluate the efficacy and safety of IPL compared to palpebral gland massage and warm compresses	Prospective, randomised controlled trial	132 total; IPL: 66; control: 66
8.	Yang, Pazo, Zhang, et al. (2021) China	Evaluate the efficacy of IPL in alleviating signs and symptoms of contact lens associated DED	Prospective, randomised, examiner masked	76 total; IPL: 38; control: 38
9.	Wu et al. (2020) China	Evaluate different patterns of IPL therapy in treating patients with MGD	Prospective, randomised, double masked, treatment study	62 total; 'Optimal Pulse Technology': 29; 'Intense Regulated Pulsed Light': 33
10.	Xue et al. (2020) New Zealand	Evaluate long-term cumulative effect of IPL in MGD. Comparing placebo, four or five light pulses	Prospective, randomised, double masked, placebo controlled	87 total; placebo: 30; 4 flashes: 28; 5 flashes: 29
11.	Wu, Xu, et al. (2022) China	Compare treatment efficacy of IPL alone versus IPL combined with heated eye mask in post-LASIK dry eye patients	Prospective, randomised	50 total, 25 in each group
12.	Xu et al. (2022) China	Compare efficacy of IPL and heated eye mask in treating contact lens related dry eye	Prospective, randomised, examiner masked	60 total, 30 in each group

Number of treatments	Device/length of follow-up	Additional treatment to IPL	Adverse events	Results/conclusion
3 (D1, D15, D45)	E>Eye/45 days	NR	NR	Improved lipid layer grade and NiBUT in treated eyes. IPL shows therapeutic potential for MGD, improves tear film quality, and reduces symptoms of dry eye
Three sessions, interval not described	Lumenis M22/90 days	No	NR	IPL improved OSDI, lid margin abnormalities, conjunctival congestion, MQ, ME, TBUT and CFS. IPL eradication rate was 100% vs 75% with tea tree oil
3 (D1, D15, D45)	E>Eye/6 months	Artificial tears four times a day, lid scrubs and warm compress	No	TBUT, ME, MQ and OSDI improved more in IPL group. Significant changes in IL-1RA levels in both groups, no changes in IL-6 levels
4-week intervals, number of sessions not reported	Lumenis M22/1 month	Sodium hyaluronate eye drops four times a day in both groups	NR	OSDI, TBUT, CFS and ME improved in both groups. TBUT and ME improved more in IPL group. The IPL group had a transient decrease in IL-17A and IL-1 β concentration at 1 week compared to tobramycin/dexamethasone with warm compress cohort
3 (D0, D15, D45)	E>Eye/75 days	Lid margin hygiene, artificial tears, azithromycin eyedrops, warm compresses and massage in both groups	No	OSDI, NiBUT, TBUT, MG expressibility, meibum quality and tear osmolarity improved in both groups. The IPL group showed significantly greater improvement of NiBUT, bulbar and limbal redness scores. Only the control group demonstrated improved tear film volume
3 (D0, D21, D42)	Lumenis M22/3 months	Continuation of artificial tears, discontinuation of any other topical or systemic DED/MGD treatment	No	Improved TFLL, NiBUT, MG dropout, MQ, ME, OSS, OSDI and decreased use of artificial tears in patients receiving IPL compared to controls
1	RH-I1504005/30 days	NR	No	IPL is more effective in treating MGD than eyelid massage and warm compresses
2 (D0, D21)	Lumenis M22/42 days	Preservative free artificial tears only	No	Improved OSDI, NiBUT, tear film lipid layer, MG quality and expressibility. Decreased use of artificial tears
'Optimal Pulse Technology': three sessions at 3-week intervals; 'Intense Regulated Pulsed Light': four sessions (D1, D15, D45, D75)	Lumenis M22 and E>Eye/3 months	Artificial tears only	No	Compared to baseline, both groups showed improvement in signs and symptoms.
4 (D0, D15, D45, D75)	E>Eye/105 days	No	No	Significant improvement of symptomatology, MG capping, LLT and inhibited growth of <i>Corynebacterium macginleyi</i> were observed in both treatment groups compared to controls. Five-flash IPL treatment showed superior clinical efficacy
Two sessions at 2-week intervals	Lumenis M22/28 days	Sodium hyaluronate in both groups	NR	Improved in both groups: NiBUT, TFLL, TMH, MQ, ME, CFS, OSDI and use of artificial tears. Improved more in IPL+heat mask: NiBUT, TMH, GQ, ME, OSDI and TFLL (greater thickness in control group, greater change in heat mask group)
Two sessions at 3-week intervals	Lumenis M22/42 days	Only artificial tears	No	Both groups improved NiBUT, TFLL, OSDI, MQ and ME. IPL group had greater improvement in all parameters

TABLE 1 (Continued)

	Study (Author/year) country of origin	Purpose	Design	Number of subjects
<i>IPL as isolated treatment modality—Prospective, not randomised studies</i>				
13.	Jiang et al. (2016) China	Evaluate safety and efficacy of IPL in MGD	Prospective open-label study	40
14.	Yin et al. (2018) China	Compare efficacy of IPL to eyelid hygiene	Prospective cohort-controlled study	35 total; IPL: 18; control: 17
15.	Vigo, Taroni, et al. (2019) Italy	To evaluate efficacy and to investigate predictors of positive outcomes of IPL in MGD	Prospective study	28
16.	Marta et al. (2021) Portugal	Evaluate clinical parameters in patients treated with IPL and LLLT	Prospective non-comparative study	31
17.	Di Marino et al. (2021) Italy	Evaluate the effects of IPL and LLLT in Sjögren's patients with DED	Prospective	20
18.	Pazo et al. (2021) China	Evaluate efficacy of optimal pulse technology IPL on patients with post-LASIK refractory dry eye	Prospective	36 total; IPL: 21; controls: 15
19.	Verges et al. (2021) Spain	Evaluate safety and efficacy of a novel IPL device in treating MGD	Prospective	44
20.	Fan et al. (2020) China	Evaluate efficacy of IPL on subjective quality of vision in patients with DED due to MGD	Prospective	64
21.	Yang, Pazo, Qin, et al. (2021) China	Evaluate the effect of IPL on the TFLL and subsequently corneal aberrations in MGD patients	Prospective	62
22.	Chen, Chen, et al. (2021) China	Determine factors relevant for clinical outcome of IPL	Prospective	48
23.	D'Souza et al. (2021) India	Evaluate efficacy of a single treatment of IPL+LLLT	Prospective	47
24.	Wu, Mou, et al. (2022) China	Evaluate efficacy of IPL combined with deproteinised calf blood extract for DED and nociceptive ocular pain	Prospective	23
<i>IPL as isolated treatment modality—Retrospective studies</i>				
25.	Karaca et al. (2018) Turkey	Evaluate the efficacy of intense regulated pulse light on MGD	Retrospective	26
26.	Stonecipher et al. (2019) USA	Evaluate efficacy of combined IPL and LLLT on refractive DED due to MGD	Retrospective	230
27.	Cheng et al. (2019) China	Assess changes of ocular <i>Demodex</i> infestation and MGD following IPL to investigate underlying mechanisms	Retrospective	25

Number of treatments	Device/length of follow-up	Additional treatment to IPL	Adverse events	Results/conclusion
4 (D1, D15, D45, D75)	E>eye/75 days	NR	No	Improved symptom scores, rounding of posterior margin, irregularity, telangiectasia, anterior blepharitis, TBUT and conjunctival injection
Three sessions at 4-week intervals	Lumenis M22/3 months	Artificial tears three times a day	NR	OSDI, TBUT, MQ, ME and MG dropout improved in both groups. IVCN parameters improved in IPL group only
3 (D1, D15, D45)	E>Eye/105 days	Preservative-free tear substitute and eyelid hygiene; 0.3% cortisol phosphate eye drops twice a day for 10 days after the first session of IPL	No	Improved NiBUT, LLT and tear film osmolarity. Low baseline NiBUT predictor of better response
Three sessions separated by 1 week	Eye-light with My Mask-E/6 months	Continuation of current treatment	No	Improved OSDI, blink rate, LLT and Schirmer test
Four weekly sessions	Eye-light with My Mask-E/3 months	Artificial tears suspended	No	Improved OSDI and TBUT
2 (D0, D14)	Lumenis M22/28 days	Preservative free artificial eyedrops	No	Improved OSDI, NiBUT, TFLL, ME, MQ, OSS and use of artificial tears in treatment group compared to control group. Post-LASIK refractory DED can safely and effectively be treated with IPL
4 (D1, D14, D28, D49)	Thermaeye Plus/4 months	Artificial tears only	No	Improved OSDI, osmolarity, TMH, NIBUT, OSS, eyelid margin assessments and MG assessments
Two sessions at 3-week intervals	Solari/42 days	No other treatment	No	Significantly improved OSDI, quality of vision, NIBUT, tear film lipid layer score, MG quality and expressibility. No significant difference observed in corneal fluorescein staining or conjunctival hyperaemia
Two sessions at 3-week intervals	Lumenis M22/42 days	No	No	Improved signs, symptoms, tear film stability and quality of vision
Three sessions at 2-week intervals	E>Eye/120 days	No, all other therapy halted	NR	Improved TBUT, CFS and OSDI. Potential clinical parameters that may influence treatment response include age, ST, OSDI and MGD severity
One session	Eye-light with My Mask-E/6 months	No	No	Improved OSDI, TBUT and MGE. Reduction of IL-1 β , IL-17F, MMP-9, MMP-9/TIMP1 ratio and B-cells
Four sessions at 4-week intervals	Device not reported/16 weeks	Deproteinised calf blood extract four times daily for 16 weeks	NR	Improved: visual analogue scale, OSDI, ocular pain assessment survey, patient health questionnaire-9, generalised anxiety disorder-7, Athens insomnia scale, CFS, MQ, ME, TBUT, ST, density of corneal nerves and substance P
3 (D1, D15, D45)	E>eye/180 days	NR	No	Improved ST, TBUT and SPEED score. Authors report improved OSDI in text, however, quantitative overview in Table 1 shows increasing values
NR	EPI-C Plus/1–3 months	Topical gatifloxacin and prednisolone antibiotic/steroid combination three times a day for 2 weeks, and oral doxycycline (100 mg \times 1) twice a day	No	Improved OSDI, TBUT and MGD grade
Four sessions (D1, D7, D21, D42)	Icon Aesthetic System/42 days	NR	NR	Improved OSDI, LLT, NiBUT, CFS, MQ, ME, lid margin abnormalities and all IVCN parameters. Total <i>Demodex</i> eradication rate 27.16%

TABLE 1 (Continued)

	Study (Author/year) country of origin	Purpose	Design	Number of subjects
28.	Murtaza et al. (2021) Canada	Evaluate the efficacy and safety of BBL-IPL therapy in patients with DED from MGD	Retrospective	48
29.	Solomos et al. (2021) Switzerland	Evaluate the efficacy of IPL with LLLT in MGD	Retrospective	11
30.	Perez-Silguero et al. (2021) Spain	Evaluate effectiveness of IPL with LLLT in patients refractory to conventional treatment	Retrospective	156
31.	Li, Lin, et al. (2021) China	Evaluate efficacy of IPL on allergic keratoconjunctivitis-associated ocular itch	Retrospective	35
32.	Yurttaser Ocak et al. (2020) Turkey	Evaluate the effect of IPL treatment on refractory DED due to MGD	Retrospective	43 total; mild atrophy: 22; moderate atrophy: 17; severe atrophy: 4
33.	Schuh et al. (2021) Germany	Evaluate effect of IPL in patients with MGD	Retrospective	25
34.	Arita et al. (2018) Japan	Evaluate efficacy of various treatment modalities including IPL and MGX in MGD	Retrospective	67 total; MGX: 30 eyes; IPL: 37 eyes
35.	Han et al. (2022) South Korea	Evaluate efficacy of IPL with an acne filter on moderate to severe MGD	Retrospective	35
<i>IPL as isolated treatment modality—Study design not reported</i>				
36.	Guilloto Caballero et al. (2017) Spain	Determine efficacy of IPL in ADDE and EDE	NR	36 total; 72 eyes of which 60 had undergone refractive surgery
37.	Vigo, Giannaccare, et al. (2019) Italy	Assess efficacy of IPL for treating MGD	NR	19
38.	Ahmed et al. (2019) Egypt	Evaluate the efficacy of IPL on tear proteins and lipids in MGD	NR	24 total; IPL: 12; controls: 12
39.	Zarei-Ghanavati, Hassanzadeh, Khorasani, and Ehsaei (2021) Iran	Evaluate the effect of conventional treatment and IPL on sleep quality of patients with MGD	NR	50
40.	Zhao et al. (2022) China	Evaluate clinical and lipidomic changes in MGD patients following IPL treatment	NR	36 total; IPL: 26; controls: 10
<i>IPL therapy in combination with MGX—Randomised studies</i>				
41.	Li et al. (2019) China	Assess safety and efficacy of IPL+MGX in Fitzpatrick skin types III–IV using two different filters and fluence (560 nm with 16 mJ/cm ² and 590 nm with 14 mJ/cm ² , respectively)	Prospective, randomised	40
42.	Ren et al. (2021) China	Compare the efficacy of IPL+MGX and near-infrared light+MGX treatments on signs and symptoms of DED	Prospective, randomised	130 total, 65 in each group
43.	Li et al. (2020) China	Assess the effect of IPL+MGX on the upper eyelids compared to patients receiving standard treatment to the lower eyelids	Prospective, randomised	30 total, 15 in each treatment group

Number of treatments	Device/length of follow-up	Additional treatment to IPL	Adverse events	Results/conclusion
Four monthly sessions	BroadBand Light/6 months	Continuation of current treatment	NR	Improved symptoms and meibography grade
Four weekly sessions	Eye-light with My Mask-E/6 weeks	Continuation of current treatment	No	Improved OSDI, lid margin abnormalities and TBUT
Four sessions over 3 months	Eye-light with My Mask-E/1 year	NR	No	Improved OSDI, NIBUT, osmolarity and tear meniscus height
3	Lumenis One/75 days	Eyedrops containing sodium hyaluronate and emedastine difumarate	NR	Improved signs and symptoms. Ocular itch gradually diminished
2–4 sessions at 2-week intervals	OPE/1 year	Artificial tears as needed in addition to previously prescribed ocular medications	Transient redness at treatment area in four patients	In the mild and moderate atrophy group, all parameters except Schirmer test significantly improved. No significant improvement in any parameter were observed in the severe atrophy group
3 (D1, D15, D45)	E>Eye/75 days	Continuation of current treatment	No	Improved OSDI, TBUT, ocular surface staining, conjunctival hyperaemia, lid margin abnormalities and MG quality
Four sessions at 3-week intervals	Lumenis M22/4 months	Artificial tears, warming of eyelids and lid hygiene	NR	Both MGX and IPL groups demonstrated improvement, although to a greater degree in the IPL cohort
Four sessions at 2–3-week intervals	Lumenis M22/4 months	No	No	Improved TBUT, OSS, meibum quality and consistency, lid margin telangiectasia, MGD grade, symptom score and MMP-9 levels
4 (D1, D15, D30, D45)	E>Eye/45 days	Continuation of previous DED treatment (artificial tears, food supplements)	Two patients with redness and light sensitivity	General increase in TBUT, more so following specific procedures or no surgery. Uncertain effect in ADDE
3 (D1, D15, D45)	Device not reported/45 days	Steroid eye drops and lubricants twice a day, 10 days with warm compresses	NR	Improved NiBUT, LLT and symptoms
NR	Philips Lumea SC2007/60/ Follow-up period not reported	NR	NR	Improved tear protein and lipid content and composition. Greater change in anionic phospholipids than other phospholipids
Three sessions: 2-week interval between sessions 1 and 2; 1 month between sessions 2 and 3	E>Eye/75 days	Warm compresses, eyelid massage, eyelid hygiene and eyelid margin scrub	No	OSDI, NIBUT, TBUT, tear osmolarity, ME, MQ and sleep quality all significantly improved from baseline
Three sessions at 3-week intervals	Quantum/Follow-up period not reported	No	NR	Improved OSDI, TBUT, conjunctival redness, CFS, ME and MQ. IPL significantly altered 24 lipid species, several of which correlated to clinical measurements
Three sessions: 2-week interval between 1 and 2; 4-week interval between 2 and 3	Lumenis One/10 weeks	Hyaluronic acid eye drops during treatment intervals	No	Improved TBUT and OSDI in both groups. Higher incidence of transient erythema with 560 nm filter
Three sessions at 1-month intervals	Near-infrared light: Frozen Book-150; IPL: Eysis-1/2 months	NR	No	Both modalities were effective in treating signs and symptoms of DED. IPL provided greater symptomatic relief
Four sessions at 2-week intervals	Lumenis One/14 weeks	Sodium hyaluronate eyedrops	No	Both groups showed significantly improved signs and symptoms. Patients receiving additional treatment to the upper eyelids showed greater treatment response and greater satisfaction

TABLE 1 (Continued)

	Study (Author/year) country of origin	Purpose	Design	Number of subjects
44.	Huo et al. (2022) China	Evaluate safety and efficacy of IPL+MGX in Sjögren's syndrome related dry eye	Prospective, randomised	55 total; IPL+MGX: 27; control: 28
<i>IPL therapy in combination with MGX—Prospective, not randomised studies</i>				
45.	Dell et al. (2017) USA	Estimate efficacy of IPL+MGX for reducing the number and severity of signs and symptoms of DED secondary to MGD	Prospective, multisite, interventional, single-arm, exploratory before–after study	40
46.	Albietz and Schmid (2018) Australia	Evaluate efficacy of IPL+MGX for chronic dry eye due to moderate to advanced MGD	Prospective open-label study	26
47.	Arita et al. (2018) Japan	Evaluate efficacy of IPL+MGX for refractory MGD	Prospective multicentre study	31
48.	Seo et al. (2018) South Korea	Evaluate long-term effect of IPL+MGX in MGD due to rosacea	Prospective	17
49.	Choi et al. (2019) South Korea	Evaluate efficacy of IPL+MGX in MGD	Prospective	30
50.	Toyos et al. (2019) USA	Evaluate safety and efficacy of IPL+MGX performed on the upper eyelids	Prospective	19
51.	Iradier et al. (2021) Spain	Define the predicting factors for a successful outcome with IPL+MGX in MGD	Prospective	195
52.	Huo et al. (2021) China	Evaluate the efficacy of IPL with 'Optimal Pulse Technology' and MGX in treating MGD with and without ocular <i>Demodex</i> infestation	Prospective	150 total; MGD with <i>Demodex</i> : 87; MGD without <i>Demodex</i> : 63
53.	Wei et al. (2020) China	Evaluate efficacy of IPL+MGX in treating MGD	Prospective	53
54.	Martinez-de-la-Casa et al. (2022) Spain	Evaluate efficacy of IPL+MGX in DED caused by topical glaucoma medications	Prospective	30
<i>IPL therapy in combination with MGX—Retrospective studies</i>				
55.	Toyos et al. (2015) USA	Assess clinical benefits of IPL+MGX therapy for treating DED caused by MGD	Retrospective	91
56.	Vegunta et al. (2016) USA	Assess efficacy of IPL+MGX in refractory DED	Retrospective	35
57.	Gupta et al. (2016) Canada	Evaluate clinical efficacy of IPL+MGX therapy for treating EDE	Retrospective, multicentre	100

Number of treatments	Device/length of follow-up	Additional treatment to IPL	Adverse events	Results/conclusion
Three sessions at 3-week intervals	Lumenis M22/15 weeks	Sodium hyaluronate eyedrops and continuation of warm compresses and lid hygiene	NR	At 15 weeks after treatment initiation the following had greater improvement in the treatment group: OSDI, NiBUT, CFS, lid margin abnormality and meibum quality
Four sessions at 3-week intervals	Lumenis M22/15 weeks	Continuation of standard MGD treatment	NR	Improved TBUT, CFS, SPEED, MG score and tear film osmolarity
3 (D1, W2, W6)	E>Eye/12 weeks	Continuation of standard MGD treatment	No	Improved TBUT, CFS, ME, MQ, lid margin redness, bulbar redness, limbal redness and OSDI. No change in eyelid margin bacteria colony counts, ST, osmolarity or artificial tear use
4–8 sessions depending on the meibum grade at 3-week intervals	Lumenis M22/4 weeks after final treatment	Continuation of current ocular medications	NR	Improved NiBUT, TBUT, CFS, lid margin abnormality score, meibum grade, SPEED and interferometric fringe pattern
Four sessions at 3-week intervals	Lumenis M22/1 year	Continuation of artificial tears and lid hygiene	No	Improved OSDI, NiBUT, TBUT, ME, MQ, OSS and lid margin vascularity. NiBUT, TBUT and OSS not maintained at 6 and 12 months
Three sessions at 3-week intervals	Lumenis M22/3 weeks after final treatment	Continuation of artificial tears and lid hygiene	No	Improved ME, MQ, lid margin abnormality, TBUT, OSS and OSDI. Decreased IL-4, IL-6, IL-10, IL-17A and TNF- α . Poor ME and short TBUT predictors of good response
Four sessions at 2–4-week intervals	Lumenis M22/ Time from final treatment to final examination not reported	Continuation of current treatment	No	Improved TBUT, global eye dryness scale and frequency of ocular pain
Four sessions with at least 2-week intervals	Lumenis Optima/4 weeks after final treatment	EDE: steroid eyedrops, local heat treatment for 5 minutes daily and artificial tears with lipids. Mixed: cyclosporin and autologous serum	Two patients reported transient and self-limiting visual blurring and eye-itching following the first session	Improved osmolarity, MQ, OSDI and NiBUT (left eye only). Improvement of OSDI can be predicted based on MGD grade, baseline OSDI and NiBUT
Three sessions at 3-week intervals	Lumenis M22/3 months	Sodium hyaluronate eyedrops	NR	<i>Demodex</i> eradication rate was 83% at 3 months. Both groups showed improved OSDI, conjunctival congestion, TBUT, corneal and conjunctival staining, lid margin abnormalities, MG dropout and expressibility and meibum quality
Three sessions at 3–4-week intervals	RH-1/4 weeks after final treatment	No	NR	Improved OSDI, meibum quality and expressibility, lid margin abnormalities and ocular surface staining. Corneal nerve fibre length increased
Four sessions at 2-week intervals	Lumenis Optima/4 weeks after final treatment	1 or more topical glaucoma medication	NR	Improved symptom scores, OSS, MGE, TMH and tear film osmolarity. No change in hyperaemia, meiboscope or NiBUT
4-week intervals (during up to 30 months)	Diamond Series Q4/ Time from final treatment to final examination not reported	Steroid or NSAID eye drops	No serious. Blistering, cheek swelling, conjunctival cyst, hair loss, light sensitivity, redness. Incidence 13%	Improved TBUT and symptoms
1–4 sessions at 4–6-week intervals	Quadra Q4/6–20 months	Ketorolac twice a day for two days after treatment	NR	Improved SPEED score and ME (left eye only)
3–6 sessions at 3–6-week intervals (on average four sessions)	Quadra Q4/Time from final treatment to final examination not reported	Steroid drops 2–3 days post-procedure, continuation of current ocular medications	No	Improved lid margin oedema, facial telangiectasia, lid margin vascularity, OSDI, MQ, ME and TBUT

TABLE 1 (Continued)

	Study (Author/year) country of origin	Purpose	Design	Number of subjects
58.	Mejia et al. (2019) Colombia	Assess efficacy of MGX+IPL as supplementary treatment in DED	Retrospective	25
59.	Min et al. (2022) South Korea	Evaluate difference in treatment effect and pain in treating MGD with IPL+MGX using a new light guide compared to traditional light guide	Retrospective	85 total; new 6 mm: 39; standard 8 mm: 46
60.	Li, Liu, et al. (2021) China	Evaluate the effect of IPL+MGX on clinical parameters and inflammatory cytokines	Retrospective	32
61.	Zhang-Nunes et al. (2021) USA	Evaluate safety and efficacy of an augmented BroadBand Light protocol IPL+MGX in treating MGD and DED	Retrospective	47
62.	Tang et al. (2021) China	Evaluate clinical changes in patients with MGD following treatment with IPL and MGX	Retrospective	44
63.	Lee et al. (2021) South Korea	Evaluate effect of IPL+MGX on levels of MMP-9 and clinical outcomes in moderate and severe MGD	Retrospective	23
64.	Caravaca et al. (2022) Spain	Evaluate efficacy of IPL+MGX in treatment of chalazion	Retrospective	19 patients; 24 eyes (26 chalazions)
65.	Chung, Rhim, & Park (2022) South Korea	Evaluate safety and efficacy of combination therapy with IPL, MGX and thermal pulsation for refractory MGD	Retrospective	23
66.	Chung, Han, et al. (2022) South Korea	Evaluate subjective and objective outcome following IPL+MGX on upper and lower eyelids compared to IPL+MGX on lower eyelids only	Retrospective	115 total; upper and lower: 75; lower only: 40
67.	Kim and Min (2022) South Korea	Compare treatment efficacy of a novel dual band filter (vascular filter) to that of a conventional filter	Retrospective	89 total; novel filter: 47; conventional filter: 44
<i>Studies comparing IPL with MGX to IPL or MGX alone</i>				
68.	Liu et al. (2017) China	Compare efficacy of IPL+MGX versus sham IPL+MGX in DED due to MGD	Prospective, randomised, double-masked controlled study	44, one eye randomised to treatment and one eye to sham treatment. Both eyes received MGX

Number of treatments	Device/length of follow-up	Additional treatment to IPL	Adverse events	Results/conclusion
Three sessions at 2-week intervals	E>Eye/4 weeks after final treatment	Continuation of previous pharmacological treatment and warm compresses	NR	Improved symptoms, TBUT, ST and OSS
Three sessions at 3-week intervals	Lumenis M22/3 weeks after final treatment	NR	No	ST decreased in both groups. Improved TBUT, CFS, lid margin abnormalities, ME, MQ and OSDI in both groups. No inter-group difference before or after treatment. The new 6mm light guide induced less pain
Three sessions at 4-week intervals	Lumenis M22/4 weeks after final treatment	Concomitant DED treatment set as exclusion factor. Patients instructed to use sodium hyaluronate eyedrops during follow-up	NR	Improved OSDI, MG secretion score and TBUT. Decreased CXCL1, CCL11, TNF- α , IFN- γ , IL-2 and IL-6. Increased TIMP-1
1–4 sessions at 4-week intervals	BroadBand Light/4–44 months, 14 months average	Continuation of current treatment	One patient with suspected conjunctival abrasion. Two patients with transient, self-limiting eyelash thinning. One patient with transient, self-limiting hyper-pigmentation	Improved OSDI, blepharitis and hordeolum frequency
Three sessions at 4-week intervals	Lumenis M22/ Time from final treatment to final examination not reported	NR	NR	IPL+MGX treatment improved symptoms, TBUT, corneal staining and MG secretions
Three sessions at 2-week intervals	Lumenis M22/2 weeks after final treatment	No concurrent treatment. 4-week washout period for topical and systemic DED treatment prior to treatment initiation	NR	Improved OSDI, TBUT, ocular surface staining, lid margin abnormalities, MQ and MMP-9 expression
2-week intervals. 11 chalazia required One session; 2 chalazia required two sessions; 13 chalazia required Three sessions; 1 chalazion did not resolve	Lumenis M22/ Time from final treatment to final examination not reported	Topical tobramycin with dexamethasone, eyelid hygiene, warm compresses and eyelid massage	No	IPL+MGX is highly effective and safe in treating chalazia
Three sessions with IPL+MGX+thermal pulsation at 3-week intervals, then three sessions of IPL+MGX at 4-week intervals followed by seven sessions of MGX at 4-week intervals	Lumenis M22/1 year	NR	No serious adverse events. Three patients reported self-limiting gritty sensation and discharge for 1 day	Improvement of NiBUT, LLT, MGE and OSDI
Four sessions at 2–3-week intervals	Lumenis M22/4 weeks after final treatment	Sodium hyaluronate eyedrops	No	TBUT, CFS, symptoms, meibum grade and quality and MMP-9 expression improved in both groups. Lid margin telangiectasia improved in cohort treated on upper and lower eyelids. Treatment of all 4 eyelids may provide additional treatment effect
Four sessions at 4-week intervals	Lumenis M22/4 months	NR	No	Both groups had improved TBUT, CFS, lid margin abnormality score, ME, MQ and OSDI.
Three sessions at 4-week intervals	Lumenis M22/12 weeks	Polyethylene glycol eye drops three times a day	NR	Compared to baseline IL-6, IL-17A and PGE2 declined following treatment in both groups with a greater decline in the IPL+MGX group. IPL+MGX superior to MGX alone

TABLE 1 (Continued)

	Study (Author/year) country of origin	Purpose	Design	Number of subjects
69.	Rong, Tang, Tu, et al. (2018) China	Compare efficacy of IPL+MGX versus sham IPL+MGX in DED due to MGD	Prospective, randomised, double-masked controlled study	44, one eye treated with IPL, the other with sham treatment. Both with MGX
70.	Rong, Tang, Liu, et al. (2018) China	Compare efficacy of IPL+MGX versus sham IPL+MGX in DED due to MGD	Prospective, randomised, double-masked controlled study	28, one eye treated with IPL, the other with sham treatment. Both with MGX
71.	Shin et al. (2021) South Korea	Evaluate efficacy of IPL+MGX compared to IPL alone for MGD	Prospective, randomised crossover clinical trial	60 total; Group 1: 33; Group 2: 27
72.	Arita et al. (2019) Japan	Compare efficacy and safety of IPL+MGX versus MGX for treating refractory MGD	Prospective, randomised controlled trial	45; one eye IPL+MGX and one eye MGX only
73.	Chen, Li, et al. (2021) China	Compare treatment efficacy of IPL+MGX compared to IPL alone or MGX alone	Prospective, randomised	100 total; IPL+MGX: 35; IPL: 33; MGX: 32
74.	Sagaser et al. (2021) USA	Evaluate TGF- β and ocular microbiome following IPL+MGX or MGX alone in patients with ocular rosacea	Prospective, randomised	20 total, 10 in each group
75.	Yan et al. (2021) China	Compare the efficacy of IPL+MGX to warm compresses+MGX in treating DED due to MGD	Prospective, randomised controlled trial	120 total, 60 in each group
76.	Toyos et al. (2022) USA	Compare safety and efficacy of IPL+MGX to MGX alone	Prospective, randomised controlled trial	82 subjects completed the study. IPL+MGX: 39; Sham treatment+MGX: 43

Number of treatments	Device/length of follow-up	Additional treatment to IPL	Adverse events	Results/conclusion
Three sessions at 4-week intervals	Lumenis M22/9 months	No	Mild pain, burning, mild redness of the eyelids	TBUT, CFS, SPEED and MG secretion score improved in study eyes. SPEED and CFS improved in control eyes. IPL + MGX superior to MGX alone
Three sessions at 4-week intervals	Lumenis M22/4 weeks after final treatment	No	NR	MGYSS improved in IPL + MGX group only and was persistently improved at 9 months. TBUT improved in IPL + MGX group only up to 6 months, returned to baseline at 9 months. SPEED score and CFS improved in both groups with no inter-group difference. IPL + MGX superior to MGX alone concerning MGYSS and TBUT
Four sessions at 2-week intervals. Group 1: Two sessions of IPL + MGX then two sessions of IPL alone. Group 2: two sessions of IPL alone then two sessions of IPL + MGX	Lumenis M22/8 weeks	NR	No	In both groups TBUT, OSDI, OSS, ME and MQ improved. Greater improvement of TBUT was seen in IPL + MGX
Eight sessions (3 weeks apart)	Lumenis M22/32 weeks	MGX after IPL therapy for treatment group; only MGX for control group	No	SPEED score, plugging, meibum grade, NiBUT and TBUT improved in both groups. ST improved in controls only. LLT, lid margin vascularity and irregularity, MG dropout and OSS improved in IPL + MGX group only. A greater degree of improvement was seen in SPEED score, LLT, lid margin plugging and vascularity, meibum grade, NiBUT, TBUT and OSS in the IPL + MGX group. IPL + MGX superior to MGX alone
Three sessions at 3-week intervals	Lumenis M22/3 months	Patients instructed to use the same formulation of artificial tears and warm compresses	No	In the MGX group only TBUT improved. OSDI, ST, TBUT, lower eyelid margin score and lower eyelid MG dropout improved in the IPL group. In the IPL + MGX group OSDI, TBUT, OSS, lower eyelid margin score and lower eyelid MG dropout improved. IPL more effective than MGX concerning MG dropout, upper and lower eyelid margin score. IPL + MGX more effective than MGX regarding OSS, MG dropout, upper and lower eyelid margin score. IPL + MGX more effective than IPL concerning OSS
Four sessions, 4–6-week intervals	Device not reported/ Final examination on final treatment day	Tobramycin/ dexamethasone twice daily for 2 days following each treatment. Previous treatment unchanged	No	IPL + MGX had a superior effect on OSDI than MGX alone. Decreased quantities of virulent bacteria present on the ocular surface after treatment in both groups with no inter-group difference. Treatment did not influence TGF- β levels in tears
Three sessions at 3-week intervals	Lumenis M22/3 weeks after final treatment	Artificial tears three times daily in both groups	No adverse events in the IPL group. In the warm compresses group, one patient developed oedema of the lower eyelid	TBUT, SPEED, MGYSS, OSS and eyelid margin scores improved in both groups. Greater improvement of TBUT, SPEED and MGYSS were seen in the IPL + MGX group
Four sessions at 2-week intervals	Lumenis M22/4 weeks after final treatment	Continuation of artificial tears or warm compresses allowed	No serious AEs. Incidence in study arm: 8.9%; incidence control arm: 20.9% ($p=0.06$)	Improvement in both arms with greater effect in study arm: TBUT, MG score (based on ME and MQ), eye dryness score, number of expressible glands and MQ. OSDI and daily use of artificial tears improved equally in both arms

TABLE 1 (Continued)

	Study (Author/year) country of origin	Purpose	Design	Number of subjects
77.	Arita, Fukuoka, Mizoguchi, and Morishige (2020) Japan	Evaluate efficacy of IPL+MGX or MGX alone on patients with refractory ADDE and mild MGD	Retrospective	43 total; IPL+MGX: 23; MGX: 20
78.	Qiao et al. (2021) China	Evaluate occurrence and causes of adverse events due to IPL+MGX and in MGX alone	Retrospective	3689 total; IPL+MGX: 2282; MGX: 1407

IPL combined with meibomian gland probing

79.	Huang et al. (2019) China	Optimise treatment regimen for refractory obstructive MGD through combining intraductal MG probing and IPL	Prospective, randomised, assessor blind	45 total, 15 in each group.
-----	------------------------------	--	---	-----------------------------

Note: Devices: Eye-light with My Mask-E (Espansione Marketing S.p.A., Bologna, Italy), Lumenis M22 (Lumenis Ltd., Yokneam, Israel), Thermaeye Plus (DEKA M.E.L.A. Spa, and worldwide distributed by MDS Medical Technologies, SL, Spain), Solari (Lutronic, Ilsan, Korea), E>Eye (E-Swin, France), EPI-C Plus (Espansione group, Italy), Icon Aesthetic System (USA), BroadBand Light (Sciton, Palo Alto, CA, USA), Lumenis One (Lumenis Inc., Santa Clara, CA, USA), OPE (Espansione group, Italy), Philips Lumea SC2007/60 (Philips Netherlands), Quantum (Lumenis, USA), Frozen Book-150 (MDC medical devices Co. Ltd., Beijing, China), Eysis-1 (SHANXI Chengal technology Co. Ltd., China), RH-1 (Ruihao, Shanxi, China), Diamond Series Q4 (DermaMed Solution, LLC, Lenni, PA, USA), Quadra Q4 (DermaMed Solutions, LLC, Lenni, PA, USA), SOLARI (Lutronic Corporation, Goyang, Korea), RH-I1504005 (Shanxi Ruihao Biotechnology Co., Ltd., Taiyuan, China).

Abbreviations: ADDE, aqueous deficient dry eye; AE, adverse event; CCL, C-C motif chemokine; CFS, corneal fluorescein staining; CXCL, chemokine ligand; D, day; DED, dry eye disease; DHA, docosahexaenoic acid; EDE, evaporative dry eye disease; EPA, eicosapentaenoic acid; IFN- γ , interferon gamma; IL-6, interleukin 6; IL-1 Ra, interleukin 1 receptor agonist; IL-17A, interleukin 17A; IL-1 β , interleukin 1 β ; IPL, Intense pulsed light; IVCN, in vivo confocal microscopy; LASIK, laser-assisted in situ keratomileusis; LLLT, low-level light therapy; LLT, lipid layer thickness; ME, meibum expressibility; MG, meibomian gland; MGD, meibomian gland dysfunction; MGX, meibomian gland expression; MGYSS, meibomian gland yielding secretion score; MMP-9, matrix metalloproteinase-9; MQ, meibum quality; NIBUT, noninvasive break-up time; NR, not reported NSAID, nonsteroidal anti-inflammatory drugs; OSS, ocular surface staining; TBUT, tear film break-up time; TFLL, tear film lipid layer; TGF-B, transforming growth factor beta; TIMP, tissue inhibitor of metalloproteinases; TMH, tear meniscus height; TNF- α , tumour necrosis factor alpha.

microvasculature, cells and organelles through pulsed radiation in 1983 (Anderson & Parrish, 1983). They reported a highly targeted approach with no damage to surrounding tissues. The first commercially available intense pulsed light (IPL) medical device, PhotoDerm VL (Lumenis Ltd.), was announced in 1994. It was based on a high-intensity flashlamp, developed for treating cutaneous vascular irregularities, introduced by Goldman and Eckhouse in 1990 (Babilas et al., 2010; Goldman, 1997). Rolando Toyos presented the foundational report on IPL for treating DED in 2002 upon observing the beneficial effects of IPL on MGD in patients treated for facial rosacea (Toyos et al., 2015). They reported decreased facial erythema and improved signs and symptoms of MGD.

2.2 | Biophysical properties

The light emitted from IPL systems is high intensity, pulsed and polychromatic, with a wavelength range of 500–1200 nm (Raulin et al., 2003; Tashbayev et al., 2020). This corresponds to visible light and infrared radiation, which is non-ionising, thus avoiding the deleterious effects of ultraviolet radiation that occur at 10–400 nm (Ash et al., 2017). Of the light emitted during IPL, the wide span of wavelengths ensures that the three key chromophores of human skin (melanin, water and haemoglobin) are targeted (Weijie et al., 2017). The depth of penetration and behaviour of the absorbed light are functions of the wavelength to produce heat and selective photothermolysis

Number of treatments	Device/length of follow-up	Additional treatment to IPL	Adverse events	Results/conclusion
Four sessions at 3-week intervals	Lumenis M22/12 weeks after final treatment	Continuation of current treatment	NR	SPEED score, meibum grade and OSS improved in both groups. LLT, eyelid plugging and vascularity, NiBUT and TBUT improved in IPL+MGX group only. SPEED score, LLT, lid margin plugging and vascularity, meibum grade, NiBUT, TBUT and OSS improved to a greater degree in the IPL+MGX cohort. MG dropout and ST did not change in either group
Conventional protocol: IPL+MGX: Four sessions at 2–3-week intervals; MGX alone: 1-week intervals for 1–3 months. Deviations from the conventional protocol described in article	SOLARI/Clinical data not reported	NR	No serious AEs in either group. IPL+MGX: 74 AEs, incidence of 3.24%, of which 14 are described as significant; MGX alone: 27 AEs, incidence of 1.92%, of which 4 are described as significant	Both IPL+MGX and MGX alone are described as safe therapies with low risk of AEs
Group 1: IPL only, three sessions at 3-week intervals; Group 2: one session of MG probing; Group 3: MG probing followed by three sessions of IPL at 3-week intervals	Lumenis M22/6 months	Artificial tears four times daily	One patient in the IPL group developed blepharoconjunctivitis after two treatments. Several (number not described) patients receiving MG probing developed transient subcutaneous ecchymosis of the eyelids following injection of anaesthetics	All groups experienced improved symptoms, TBUT, ocular surface staining, lid margin abnormalities and MG grade. MG probing combined with IPL demonstrated superior effect in relieving all signs and symptoms

(Figure 3). Specific cut-off filters and clinical parameters, such as the Fitzpatrick scale for skin type, are commonly employed to achieve the optimal wavelength to a target structure at a given depth and minimise the risk of adverse events by adjusting the treatment intensity (Giannaccare et al., 2019; Goldman, 1997; Li et al., 2019; Raulin et al., 2003; Weijie et al., 2017). Furthermore, the fluence, duration and intervals between pulses can be manipulated, influencing the amount of energy density (J/cm^2) delivered and allowing for appropriate thermal relaxation of the target tissue avoiding damage to surrounding structures (Raulin et al., 2003; Weijie et al., 2017). IPL treatment is occasionally combined with low-level light therapy (LLLT), a form of low-intensity, longer lasting photobiomodulation that exposes the tissue to non-ionising radiation, typically between 400 and 1100 nm (Markoulli et al., 2021).

3 | METHODS

The aim of the current article is to critically appraise the clinical studies published to date assessing the use of IPL to treat DED. A PubMed search was conducted on July 19, 2022, with the search terms ‘intense pulsed light AND dry eye disease’, ‘intense pulsed light AND dry eye’, and ‘intense pulsed light AND meibomian gland dysfunction’. These terms returned 91, 95 and 101 results, respectively. The exclusion criteria were as follows: abstract only, non-English language, review articles, letters to the editor and full text not available. Based on these exclusions, 79 articles remained. Forty-eight were prospective studies, 26 were retrospective studies and five did not report study design. In the following review, we give an overview of all clinical studies performed. A special focus in the results and discussion is given to randomised controlled studies, either comparing the

TABLE 2 Overview of studies reporting change of a given clinical parameter following IPL treatment.

Study (Author/year)	Design	OSDI	SPEED	TBUT	NIBUT	LLT	BR/LR	OSS	ST	MGM	Osm	MQ	ME	MGYSS	LMA
<i>IPL as isolated treatment modality</i>															
1. Craig et al. (2015)	Prospective, randomized	NA	+	NA	+	+	NA	NA	NA	NA	0	NA	NA	NA	NA
2. Zhang et al. (2019)	Prospective, randomized	+	NA	+	NA	NA	NA	+	0	NA	NA	+	+	NA	+
3. Piyacomn et al. (2019)	Prospective randomized	+	NA	+	NA	0	NA	NA	0	+	0	+	+	NA	NA
4. Gao et al. (2019)	Prospective, randomized	+	NA	+	NA	NA	NA	+	NA	0	NA	0	+	NA	NA
5. Zarei-Ghanavati, Hassanzadeh, Azimi Khorasani, et al. (2021)	Prospective, randomized	+	NA	+	+	NA	+	0	NA	0	+	+	+	NA	0
6. Song et al. (2021)	Prospective, randomized	+	NA	NA	+	+	NA	+	NA	+	NA	+	+	NA	NA
7. Yan and Wu (2021)	Prospective, randomized	NA	NA	NA	NA	NA	NA	NA	+	NA	NA	+	NA	NA	NA
8. Yang, Pazo, Zhang, et al. (2021)	Prospective, randomized	+	NA	NA	+	+	0	+	NA	NA	NA	+	+	NA	NA
9. Wu et al. (2020)	Prospective, randomized	+	NA	+	+	NA	+	0	0	+	NA	NA	NA	+	+
10. Xue et al. (2020)	Prospective, randomized	+	+	NA	0	+	0	0	NA	0	0	0	0	NA	+
11. Wu, Xu, et al. (2022)	Prospective, randomised	+	NA	NA	+	+	NA	+	NA	NA	NA	+	+	NA	NA
12. Xu et al. (2022)	Prospective, randomised	+	NA	NA	+	+	0	0	NA	NA	NA	+	+	NA	NA
13. Jiang et al. (2016)	Prospective	NA	NA	+	NA	NA	+	0	NA	NA	NA	+	+	NA	+
14. Yin et al. (2018)	Prospective	+	NA	+	NA	NA	NA	+	NA	+	NA	+	+	NA	NA
15. Vigo, Taromi, et al. (2019)	Prospective	0	NA	NA	+	+	NA	NA	NA	0	+	NA	NA	NA	NA
16. Marta et al. (2021)	Prospective	+	NA	NA	0	+	NA	0	+	-	-	NA	NA	NA	NA
17. Di Marino et al. (2021)	Prospective	+	NA	+	NA	NA	NA	NA	0	NA	NA	NA	NA	NA	NA
18. Pazo et al. (2021)	Prospective	+	NA	NA	+	+	NA	+	NA	NA	NA	+	+	NA	NA
19. Verges et al. (2021)	Prospective	+	NA	NA	+	NA	NA	+	NA	+	+	+	+	NA	+
20. Fan et al. (2020)	Prospective	+	NA	NA	+	+	0	0	NA	NA	NA	+	+	NA	NA
21. Yang, Pazo, Qin, et al. (2021)	Prospective	+	NA	NA	+	+	0	0	NA	NA	NA	+	+	NA	NA
22. Chen, Chen, et al. (2021)	Prospective	+	NA	+	NA	NA	NA	+	0	NA	NA	NA	NA	NA	0
23. D'Souza et al. (2021)	Prospective	+	NA	+	NA	NA	NA	NA	0	NA	NA	0	+	NA	NA
24. Wu, Mou, et al. (2022)	Prospective	+	NA	+	NA	NA	NA	+	+	NA	NA	+	+	+	NA
25. Karaca et al. (2018)	Retrospective	?	+	+	NA	NA	NA	0	+	NA	NA	0	0	NA	0
26. Stonecipher et al. (2019)	Retrospective	+	NA	+	NA	NA	NA	NA	NA	NA	NA	+	NA	NA	NA
27. Cheng et al. (2019)	Retrospective	+	NA	NA	+	+	NA	+	0	+	NA	+	+	NA	+
28. Murtaza et al. (2021)	Retrospective	NA	NA	NA	0	NA	+	NA	NA	+	NA	NA	NA	NA	NA
29. Solomos et al. (2021)	Retrospective	+	NA	+	NA	NA	NA	0	+	+	NA	NA	NA	NA	+
30. Perez-Silguero et al. (2021)	Retrospective	+	NA	NA	+	NA	NA	NA	NA	NA	+	NA	NA	NA	NA
31. Li, Lin, et al. (2021)	Retrospective	NA	NA	+	NA	NA	NA	NA	NA	NA	NA	NA	NA	NA	NA

TABLE 2 (Continued)

	Study (Author/year)	Design	OSDI	SPEED	TBUT	NiBUT	LLT	BR/LR	OSS	ST	MGM	Osm	MQ	ME	MGYSS	LMA
32.	Yurttaser Ocak et al. (2020)	Retrospective	+	NA	NA	+	NA	NA	+	0	+	NA	NA	NA	NA	NA
33.	Schuh et al. (2021)	Retrospective	+	NA	+	NA	NA	+	+	0	0	NA	+	+	NA	+
34.	Arita, Fukuoka, and Kawashima (2020) and Arita, Fukuoka, Mizoguchi, and Morishige (2020)	Retrospective	NA	+	+	NA	0	NA	+	+	NA	NA	+	+	NA	+
35.	Han et al. (2022)	Retrospective	NA	NA	+	NA	NA	NA	+	0	NA	NA	+	+	NA	+
36.	Guilloto Caballero et al. (2017)	NR	NA	NA	NA	+	NA	NA	NA	+	NA	NA	NA	NA	NA	NA
37.	Vigo, Giannaccare, et al. (2019)	NR	0	NA	NA	+	+	NA	NA	NA	0	0	NA	NA	NA	NA
38.	Ahmed et al. (2019)	NR	NA	NA	NA	NA	NA	NA	NA	NA	NA	NA	NA	NA	NA	NA
39.	Zarei-Ghanavati, Hassanzadeh, Khorasani, and Ehsaei (2021)	NR	+	NA	+	+	NA	+	NA	0	0	+	+	+	NA	NA
40.	Zhao et al. (2022)	NR	+	NA	+	NA	NA	+	+	NA	0	NA	+	+	NA	NA
<i>IPL therapy in combination with MGX</i>																
41.	Li et al. (2019)	Prospective, randomised	+	NA	+	NA	NA	NA	NA	NA	NA	NA	NA	NA	NA	NA
42.	Ren et al. (2021)	Prospective, randomised	NA	NA	0	NA	NA	NA	NA	NA	0	NA	+	+	NA	NA
43.	Li et al. (2020)	Prospective, randomised	+	NA	+	NA	NA	NA	NA	NA	NA	NA	NA	NA	NA	NA
44.	Huo et al. (2022)	Prospective, randomised	+	NA	NA	+	NA	+	+	+	0	NA	+	+	NA	+
45.	Dell et al. (2017)	Prospective	NA	+	+	NA	0	NA	+	NA	+	+	+	+	NA	+
46.	Albietz and Schmid (2018)	Prospective	+	NA	+	NA	NA	+	+	0	NA	0	+	+	NA	NA
47.	Arita et al. (2018)	Prospective	NA	+	+	+	NA	NA	+	0	0	NA	+	+	NA	+
48.	Seo et al. (2018)	Prospective	+	NA	+	+	NA	NA	+	NA	NA	NA	+	+	NA	+
49.	Choi et al. (2019)	Prospective	+	NA	+	NA	0	NA	+	NA	0	NA	+	+	NA	+
50.	Toyos et al. (2019)	Prospective	NA	NA	+	NA	NA	NA	NA	NA	NA	NA	NA	NA	NA	NA
51.	Iradier et al. (2021)	Prospective	+	NA	NA	+	NA	NA	NA	+	0	+	+	+	NA	NA
52.	Huo et al. (2021)	Prospective	+	NA	+	NA	NA	+	+	0	+	NA	+	+	NA	+
53.	Wei et al. (2020)	Prospective	+	NA	0	NA	NA	NA	+	NA	NA	NA	+	+	NA	+
54.	Martinez-de-la-Casa et al. (2022)	Prospective	+	+	NA	0	NA	0	+	NA	0	+	NA	+	NA	NA
55.	Toyos et al. (2015)	Retrospective	NA	NA	+	+	NA	NA	NA	NA	NA	NA	NA	NA	NA	NA
56.	Vegunta et al. (2016)	Retrospective	NA	+	NA	NA	NA	NA	NA	NA	NA	NA	NA	+	NA	NA
57.	Gupta et al. (2016)	Retrospective	+	NA	+	NA	NA	NA	NA	NA	NA	NA	+	+	NA	+
58.	Mejia et al. (2019)	Retrospective	NA	NA	+	NA	NA	NA	+	+	NA	NA	NA	NA	NA	NA
59.	Min et al. (2022)	Retrospective	+	NA	+	NA	0	NA	+	-	NA	NA	+	+	NA	+
60.	Li, Liu, et al. (2021)	Retrospective	+	NA	+	NA	NA	NA	NA	NA	NA	NA	NA	NA	+	NA

(Continues)

TABLE 2 (Continued)

	Study (Author/year)	Design	OSDI	SPEED	TBUT	NIBUT	LLT	BR/LR	OSS	ST	MGM	Osm	MQ	ME	MGYSS	LMA
61.	Zhang-Nunes et al. (2021)	Retrospective	+	NA	NA	NA	NA	NA	NA	NA	NA	NA	NA	NA	NA	NA
62.	Tang et al. (2021)	Retrospective	+	+	+	NA	NA	NA	+	NA	0	NA	NA	NA	+	NA
63.	Lee et al. (2021)	Retrospective	+	NA	+	NA	NA	NA	+	NA	NA	NA	+	+	NA	+
64.	Caravaca et al. (2022)	Retrospective	NA	NA	NA	NA	NA	NA	NA	NA	NA	NA	NA	NA	NA	NA
65.	Chung, Rhim, & Park (2022)	Retrospective	+	NA	NA	+	+	NA	NA	NA	NA	NA	NA	+	NA	NA
66.	Chung, Han, et al. (2022)	Retrospective	NA	NA	+	NA	NA	NA	+	0	NA	NA	+	+	NA	+
67.	Kim and Min (2022)	Retrospective	+	NA	+	NA	0	NA	+	0	NA	NA	+	+	NA	+
<i>Studies comparing IPL with MGX to IPL or MGX alone</i>																
68.	Liu et al. (2017)	Prospective, randomised	NA	NA	NA	NA	NA	NA	NA	NA	NA	NA	NA	NA	NA	NA
69.	Rong, Tang, Tu, et al. (2018)	Prospective, randomised	NA	+	+	NA	NA	NA	+	NA	0	NA	NA	NA	+	NA
70.	Rong, Tang, Liu, et al. (2018)	Prospective, randomised	NA	+	+	NA	NA	NA	+	NA	NA	NA	NA	NA	+	NA
71.	Shin et al. (2021)	Prospective, randomised	+	NA	+	NA	NA	NA	+	NA	0	NA	+	+	NA	NA
72.	Arita et al. (2019)	Prospective, randomised	NA	+	+	+	+	NA	NA	0	+	NA	+	+	NA	+
73.	Chen, Li, et al. (2021)	Prospective, randomised	+	NA	+	0	NA	NA	+	+	+	NA	NA	NA	+	+
74.	Sagaser et al. (2021)	Prospective, randomised	+	NA	NA	NA	NA	NA	NA	NA	0	NA	NA	NA	+	NA
75.	Yan et al. (2021)	Prospective, randomised	NA	+	+	NA	NA	NA	+	NA	NA	NA	NA	NA	+	+
76.	Toyos et al. (2022)	Prospective, randomised	+	NA	+	NA	NA	NA	NA	NA	0	NA	+	+	NA	NA
77.	Arita, Fukuoka, Mizoguchi, and Morishige (2020)	Retrospective	NA	+	+	+	+	NA	+	0	0	NA	+	+	NA	+
78.	Qiao et al. (2021)	Retrospective	NA	NA	NA	NA	NA	NA	NA	NA	NA	NA	NA	NA	NA	NA
<i>IPL combined with meibomian gland probing</i>																
79.	Huang et al. (2019)	Prospective, randomised	NA	+	+	NA	NA	NA	+	NA	NA	NA	+	+	NA	+

Abbreviations: BR/LR, bulbar redness/limbal redness; IPL, intense pulsed light; LLT, lipid layer thickness; LMA, lid margin abnormality; ME, meibomian gland expression; MGM, meibomian gland morphology; MGX, meibomian gland expression; MGYSS, meibomian gland yielding secretion score; MQ, meibum quality; NA, not applicable; NIBUT, non-invasive break up time; OSDI, Ocular Surface Disease Index; Osm, osmolarity; OSS, ocular surface staining; SPEED, standard patient evaluation of eye dryness; ST, Schirmer test; TBUT, tear break-up time; +, improved; -, worsened.

TABLE 3 Percentage of studies ($n=79$) reporting change of a given clinical parameter following IPL treatment.

	OSDI	SPEED	TBUT	NIBUT	LLT	BR/LR	OSS	ST	MGM	Osm	MQ	ME	MGYSS	LMA
Reported	67.1%	18.9%	62.0%	39.2%	27.8%	20.3%	60.8%	38.0%	43.0%	17.7%	58.2%	57.0%	11.4%	38.0%
Improved	94.3%	100%	95.9%	83.9%	72.7%	62.5%	79.2%	33.3%	38.2%	57.1%	91.3%	95.6%	100%	90%
No difference	5.7%	0%	4.1%	16.1%	27.3%	37.5%	20.8%	63.3%	58.8%	35.7%	8.7%	4.4%	0%	10%
Worsened	0%	0%	0%	0%	0%	0%	0%	3.3%	2.9%	7.1%	0%	0%	0%	0%

Abbreviations: BR/LR, bulbar redness/limbal redness; LMA, lid margin abnormality; ME, meibomian gland expression; MGM, meibomian gland morphology; MGYSS, meibomian gland yielding secretion score; MQ, meibum quality; NIBUT, non-invasive break up time; OSDI, Ocular Surface Disease Index; Osm, osmolality; OSS, ocular surface staining; SPEED, standard patient evaluation of eye dryness; ST, Schirmer test; TBUT, tear break up time.

treatment effects of IPL to sham treatment or to other treatment modalities; studies including biochemical data; studies evaluating the additional treatment effect of the upper eyelids and studies examining the duration of the treatment effect.

4 | RESULTS

Included studies are summarised in [Table 1](#). Fifty-three studies examined symptoms through ocular surface disease index (OSDI) and 15 through standard patient evaluation of eye dryness (SPEED) questionnaires, of which 50 and 15 reported improvements, respectively ([Table 2](#)). Regarding tear film stability, between 84% and 95% of the studies found improvement following treatment, depending on mode of measurement. Moreover, the vast majority found improved meibum expressibility (ME) or meibum quality (MQ). Several studies found decreased ocular surface staining, although some reported no change; none observed an increase. Concerning tear production, 10 studies reported increased Schirmer test (ST) results, 19 found no difference and one study observed a decreased output. Interestingly, among the 34 studies comparing meibography before and after treatment, 13 found a decrease in MG dropout while one reported an increase. The percentages of studies reporting changes in various clinical parameters are presented in [Table 3](#).

4.1 | IPL as an isolated treatment modality

Forty studies with IPL as standalone treatment modality were included. Of these, 24 were prospective, of which 12 were randomised. Eleven studies were retrospective, whereas five studies did not report on study design.

4.1.1 | Randomised studies

Among the 12 randomised studies included in this review, the number of treatment sessions with IPL ranged from one to four, with intervals of 2–4 weeks. The number of included subjects ranged from 28 to 114. Five studies compared IPL to sham treatment, and seven studies compared it to other treatments ([Table 2](#)). Among the studies evaluating the following parameters, 64% found improved symptoms scores, 91% showed improved tear film stability and 80% showed improved ME or MQ when comparing IPL to sham or other treatments.

4.1.2 | Prospective, non-randomised studies

Twelve studies are included in this category. The number of treatment sessions ranged from one to four, and the treatment intervals ranged from 1 to 4 weeks. The number of subjects varied from 20 to 64. One study included a control group receiving no treatment (Pazo et al., 2021), and one study compared treatment effect to that of eyelid hygiene (Yin et al., 2018). Compared to baseline all reported improved symptoms, 92% reported improved

tear film stability, and all eight studies evaluating ME or MQ found improvement.

4.1.3 | Retrospective studies

Eleven studies were included in this group. The number of sessions ranged from two to four, treatment intervals ranged from 1 to 4 weeks, and the numbers of included subjects were between 11 and 230. All studies reported improved symptom scores, 91% documented improved tear film stability, whereas 83% of the six studies evaluating glandular secretion found improved parameters.

Ahmed et al. examined the effect of IPL on tear proteins and lipids in 12 patients diagnosed with MGD and 12 controls (Ahmed et al., 2019). Protein and lipid content were measured through absorbance. Quantification of phospholipids was achieved through thin-layer chromatography. When comparing protein and lipid profiles of controls and patients before treatment, increased total protein content and decreased total lipid concentration were found among MGD patients. Specifically, the authors described increased albumin and decreased lactoferrin and lysozyme as well as decreased cholesterol, triglycerides and phospholipids. Following treatment, all values of MGD patients showed significant changes, with values shifting closer to that of healthy controls.

A later study employed liquid chromatography tandem mass spectrometry to analyse and compare the lipidomic profiles of 10 healthy controls and 26 MGD patients before and after IPL treatment (Zhao et al., 2022). In total, 323 lipid species were identified, 41 of which differed between subjects and controls at baseline, and 24 lipid species altered following treatment. Several lipid species correlated with clinical measures such as TBUT, MQ, conjunctival redness and tear meniscus height (TMH).

4.2 | IPL therapy in combination with meibomian gland expression

There were 27 studies evaluating the effects of IPL treatment combined with MG expression (MGX). Out of these, four were randomised, 10 were prospective non-randomised and 13 were retrospective studies.

4.2.1 | Randomised studies

Four studies are included in this group, with three studies employing three treatment sessions and one using four. Treatment intervals ranged from 2 to 4 weeks and included subjects from 30 to 130 in number. Compared to baseline, all four studies reported improved symptom scores following treatment, and 75% found improved tear film stability.

Only one study implemented a control group not receiving any active treatment, all subjects were prescribed sodium hyaluronate eyedrops and could continue lid hygiene and warm compresses (Huo et al., 2022). Both groups experienced improved OSDI, TMH, non-invasive

break-up time (NiBUT), ocular surface staining (OSS), ME and MQ. The treatment group demonstrated betterment to a greater degree concerning OSDI, NiBUT, OSS, lid margin abnormalities and MQ.

Another study compared MGX paired with either photobiomodulation through near-infrared light (800–960 nm, 12 J/cm², 10 pulses) or IPL (580–1200 nm, 12 J/cm², 10 pulses) (Ren et al., 2021). Both groups demonstrated improved ME, MQ and total symptoms score. Only the near-infrared light group achieved improved TMH while the IPL group had greater improvement of ME, MQ and total symptoms score. TBUT did not change in either group.

4.2.2 | Prospective, non-randomised studies

Among the 10 included studies, the number of treatment sessions varied from three to eight, treatment intervals ranged from 2 to 4 weeks, and the number of included subjects extended from 17 to 195. No studies included untreated controls. Compared to baseline, all studies found improved symptom scores following treatment. Improved tear film stability was found in 80% and improved glandular secretions in 90%. Corneal nerve fibre length measured with IVCN and analysed through artificial intelligence algorithms demonstrated a significant increase following treatment (Wei et al., 2020). One study including 26 patients, evaluated treatment effect on bacterial load, but found no changes in bacterial cultures (Albietz & Schmid, 2018).

4.2.3 | Retrospective studies

A total of 13 retrospective studies conducted between 2015 and 2022 were included. The studies involved 23–115 participants receiving between one and thirty treatments with two to six-week intervals. Ten studies evaluated and found improved TBUT and all 13 reported improved symptom scores.

4.3 | Studies comparing combined IPL and MGX to IPL or MGX alone

Among the 11 studies included in this category, nine were randomised and prospective by design while two were retrospective. The number of treatment sessions ranged from three to eight, and treatment intervals between 2 and 6 weeks. The included subjects varied in number from 20 to 120 in studies evaluating treatment efficacy while one study assessing occurrences of adverse events had 3689 (Qiao et al., 2021). Nine studies evaluated symptom scores, which improved in all IPL+MGX cohorts, and all but two monotherapy groups (Chen, Li, et al., 2021; Sagaser et al., 2021). All eight studies that quantified changes in tear film stability following treatment concluded with improved measures. Ten studies reported superior efficacy of IPL+MGX compared to either MGX or IPL monotherapy, while one study only evaluated the incidence

of adverse effects and did not quantitate treatment efficacy (Qiao et al., 2021). Seven studies compared IPL+MGX to MGX alone, among which 57% found greater effect of IPL+MGX on symptoms, and 71% regarding ME, MQ and tear film stability. Chen et al. randomly assigned 100 patients to receive IPL, MGX or IPL+MGX (Chen, Li, et al., 2021). In the MGX group, only TBUT improved, and at 1 month only. IPL resulted in amelioration of OSDI, ST, lower eyelid margin score (based on lid irregularity, hyperaemia, and thickness), and MG dropout at various time points. IPL+MGX decreased OSDI, OSS, lower eyelid margin score and MG dropout as well as increased TBUT. IPL and IPL+MGX were superior to MGX regarding OSS, ME, MQ and MG dropout. IPL+MGX demonstrated better results than IPL with respect to OSS.

Qiao et al. compared the incidence of adverse events in patients treated with IPL+MGX versus MGX alone (Qiao et al., 2021). The study included a total of 3689 patients, of whom 2282 were treated with IPL+MGX and 1407 only with MGX. The authors reported an incidence of 3.2% and 1.9% in the IPL+MGX and MGX cohorts, respectively. No serious adverse events were reported in either group. The authors concluded that both treatment modalities are safe but that caution should be exercised upon administering IPL treatment to patients with a history of herpes simplex keratitis, due to a possible risk of reactivation, or to patients with high myopia, due to the risk of post-procedure floaters (Qiao et al., 2021).

4.4 | Studies including IPL treatment of the upper eyelids

Sixteen of the included articles report IPL treatment of the upper eyelids (Caravaca et al., 2022; Cheng et al., 2019; Chung, Han, et al., 2022; Chung, Rhim, & Park, 2022; Gao et al., 2019; Han et al., 2022; Kim & Min, 2022; Li et al., 2020; Li, Liu, et al., 2021; Liu et al., 2017; Murtaza et al., 2021; Rong, Tang, Liu, et al., 2018; Rong, Tang, Tu, et al., 2018; Tang et al., 2021; Toyos et al., 2019; Zhang-Nunes et al., 2021). Seven studies did not report on the occurrence of adverse events, six studies reported no adverse events while three studies found non-serious adverse events such as conjunctival abrasion, self-limiting eyelash thinning, self-limiting hyper-pigmentation, gritty sensation, discharge burning and redness (Chung, Rhim, & Park, 2022; Rong, Tang, Tu, et al., 2018; Zhang-Nunes et al., 2021). Two of the studies explored whether treatment of the upper eyelid in addition to the lower eyelid would increase the treatment efficacy: one was prospective and randomised (Li et al., 2020) while the other was retrospective (Chung, Han, et al., 2022). Both studies described an additive effect of upper eyelid treatment. Li et al. found a greater increase in TBUT, OSDI and greater patient satisfaction (Li et al., 2020). Chung et al. reported a greater effect of OSS, ocular irritation symptom score, lid margin telangiectasias as well as meibum colour and consistency (Chung, Han, et al., 2022). They did not, however, find any additional effect on TBUT or levels of MMP-9. Neither study reported any adverse events in any patient cohort.

4.5 | Long-term treatment effects of IPL

Among the included trials, eight had follow-up periods of 6 months or more (Chung, Rhim, & Park, 2022; D'Souza et al., 2021; Marta et al., 2021; Piyacomn et al., 2019; Rong, Tang, Liu, et al., 2018; Seo et al., 2018; Yurttaser Ocak et al., 2020; Zhang-Nunes et al., 2021). Four of these studies employed IPL as monotherapy. One was randomised with a sham control group and found improved TBUT, MQ, ME and OSDI in the IPL cohort compared to controls after 6 months (Piyacomn et al., 2019). Two of the studies were prospective with 6-month follow-up and without control groups, one found improved OSDI, LLT, MG dropout and ST at 6 months compared to baseline with no change in NiBUT (Marta et al., 2021) while the other reported improved OSDI, TBUT and ME (D'Souza et al., 2021). Another study had a retrospective design without control group and a one-year follow-up in which they found lasting treatment effects on OSDI, daily use of ocular lubricants, NiBUT, OSS and MG dropout in patients with mild and moderate MG dropout (Yurttaser Ocak et al., 2020). No treatment effects were seen in the cohort with severe dropout. One study found persistently improved OSDI, NiBUT, LLT and ME at 1 year following LipiFlow, IPL and MGX (Chung, Rhim, & Park, 2022). In this study, however, the patients received monthly treatments with MGX for the full year. A recent study combined MGX and IPL on both upper and lower eyelids (Zhang-Nunes et al., 2021). The authors report a follow-up time of 4–40 months with an average of 14 months and subsequent improved OSDI and blepharitis. Another one-year follow-up study, however, reported lasting treatment effects on OSDI and MQ, but diminishing effects on TBUT, NiBUT and OSS, which were not significant anymore after 12 weeks (Seo et al., 2018). Similar results were published in a 9-month follow-up study where the authors reported lasting treatment effects of IPL+MGX compared to MGX alone on MGs yielding secretion score and symptoms, with the effect on TBUT losing its significance after 6 months (Rong, Tang, Liu, et al., 2018).

5 | DISCUSSION

In the last few years, we have seen a surge in studies assessing the efficacy of IPL as a treatment modality. Our research group published a review article on the use of IPL in the treatment of MGD in 2020, which included 27 studies (Tashbayev et al., 2020). In just over 2 years, that number has risen to 79, illustrating increasing worldwide scientific interest in the technology.

Among the studies evaluating IPL as a standalone treatment, 12 were randomised control trials (Craig et al., 2015; Gao et al., 2019; Piyacomn et al., 2019; Song et al., 2021; Wu et al., 2020; Wu, Xu, et al., 2022; Xu et al., 2022; Xue et al., 2020; Yan & Wu, 2021; Yang, Pazo, Qin, et al., 2021; Yang, Pazo, Zhang, et al., 2021; Zarei-Ghanavati, Hassanzadeh, Azimi Khorasani, et al., 2021; Zhang et al., 2019), and five of these compared treatment efficacy to that of sham treatment (Craig et al., 2015; Piyacomn et al., 2019; Song et al., 2021; Xue et al., 2020;

Yang, Pazo, Qin, et al., 2021; Yang, Pazo, Zhang, et al., 2021). In the sham-controlled trials, all demonstrated significantly decreased symptom score and all but one found improved tear film stability in the IPL cohorts compared to controls (Xue et al., 2020).

IPL is often combined with MGX, a procedure that can be unpleasant, painful, invasive, and time-consuming. According to the study performed by Qiao et al., the addition of MGX raises the incidence of adverse events from 1.9% to 3.2% (Qiao et al., 2021). Hence, the cost–benefit of this addition needs to be thoroughly examined. Among the seven studies included herein comparing IPL+MGX to MGX monotherapy (Arita et al., 2019; Liu et al., 2017; Rong, Tang, Liu, et al., 2018; Rong, Tang, Tu, et al., 2018; Sagaser et al., 2021; Toyos et al., 2022; Yan et al., 2021), four reported additive effect on symptoms (Arita et al., 2019; Sagaser et al., 2021; Toyos et al., 2022; Yan et al., 2021), and five found greater improvement concerning meibum characteristics and tear film stability (Arita et al., 2019; Rong, Tang, Liu, et al., 2018; Rong, Tang, Tu, et al., 2018; Toyos et al., 2022; Yan et al., 2021). Only two studies compared IPL+MGX to IPL alone, one cross-over study (Shin et al., 2021), and one study comparing IPL+MGX to both IPL and MGX alone (Chen, Li, et al., 2021). The former study reported greater improvement of TBUT in the IPL+MGX cohort, while the latter found a more profound amelioration of OSS by the addition of MGX when compared to IPL alone. Thus, there seems to be a good scientific basis for adding IPL to MGX, however, whether the addition of MGX to IPL really is beneficial, needs further research.

Most IPL devices were originally designed for treating the lower eyelids. More recently, adaptations have made treatment of the upper eyelids possible. Among the studies included herein, only two compared whether additional treatment of the upper eyelids would increase treatment effect. Only one study was prospective and randomised, and this study had a relatively small sample size of 15 patients in each group. Based on the comparative studies published so far, there is insufficient documentation and a need for larger, randomised studies exploring the risk–benefit relationship of supplementary treatment of the upper eyelids.

An additional question in need of illumination is the duration of treatment effect. In reference to studies conducted so far with follow-up times of more than 6 months, treatment effect on symptomatic relief and meibum characteristics seems to be longer lasting upwards of 1 year, while tear film stability deteriorates after about 6 months. There is, however, insufficient evidence to conclude and there is a need for larger, randomised, long-lasting controlled studies.

While most studies reported improvements in symptoms and one or more clinical parameters, some patients did not experience subjective or objective betterment. Predicting which patients are likely to benefit from IPL is highly important regarding exposure to unnecessary procedures, use of clinical and clinician resources, provision of realistic expectations, and patients' economy. A few attempts at delineating clinical predictors have been made. Vigo et al. found that a low baseline NiBUT predicted a better response (Vigo, Taroni, et al., 2019),

whereas Albiets and colleagues revealed that low baseline ME was correlated to greater symptomatic relief (Albiets & Schmid, 2018). Likewise, Choi et al. concluded that an unstable tear film and poor ME correlated to greater improvement of OSDI (Choi et al., 2019). Conversely, another study described longer TBUT, younger age, low degree of MG dropout and low meiboscore as predictors of better treatment outcome, defined as degree of change in MGs yielding secretion score (Tang et al., 2021). Finally, Iradier et al. developed a linear model to predict the change in OSDI based on baseline values of OSDI, NiBUT, and MQ (reported R^2 : 0.325; adjusted R^2 : 0.276) (Iradier et al., 2021). The former four of these five studies were smaller, including 28, 26, 30 and 44 patients, respectively. In contrast, the predictive model proposed by Iradier et al. was based on 195 patients. Larger, prospective studies are warranted to gain a deeper understanding of which clinical factors predict good treatment response. There is also a lack of studies investigating whether any specific features indicate poor response or non-response. An alternative approach to predicting treatment efficacy is understanding the underlying aetiology of various dry eye subtypes and the treatment's mechanism of action. Although the underlying mechanism(s) concerning the beneficial effects of IPL remains unknown, there are currently several working theories:

- Liquefaction of meibum: a common clinical finding among MGD patients is increased meibum viscosity and decreased expressibility (Tomlinson et al., 2011). This is partly due to an increased phase-transition temperature resulting from altered lipidomic composition (Borchman et al., 2011, 2012; Foulks et al., 2010). Thus, warming the eyelids and meibum past the elevated phase-transition temperature should promote liquefaction and facilitate expression. Several authors have promoted this as a contributory mechanism of IPL (Dell et al., 2017; Gupta et al., 2016), though others voice scepticism due to the short duration and limited effect on temperature (Albiets & Schmid, 2018; Craig et al., 2015). However, recent publications describe alterations of the lipidomic profile of DED patients following IPL treatment, thus theoretically lowering the phase-transition temperature back towards the physiological range and promoting a more lasting expressibility (Ahmed et al., 2019; Zhao et al., 2022). More extensive, prospective studies employing lipidomic analysis at several time points during treatment are warranted and currently underway by our group.
- Telangiectatic thrombosis: eyelid telangiectasia is a hallmark of MGD, and it is hypothesised that these abnormal vascular structures may work as an inducer, propagator and reservoir for pro-inflammatory mediators (Bron et al., 2017; Dell et al., 2017; Schaumberg et al., 2011). The peak absorption wavelength of haemoglobin at 578 nm allows selective photothermolysis and obliteration of telangiectasias (Gupta et al., 2016; Weijie et al., 2017). Indeed, several clinical studies have demonstrated a decrease in telangiectatic vessels following IPL treatment (Albiets & Schmid, 2018; Arita et al., 2018; Cheng et al., 2019; Gupta et al., 2016; Seo

et al., 2018). There is a need for larger, prospective studies to assess the correlation between telangiectatic thrombosis, inflammatory markers and clinical signs of inflammation following treatment.

- Inflammation: DED is a disease in which inflammation can be both an instigating and propagating factor (Bron et al., 2017). The inflammatory cascade in DED is still incompletely understood. However, further damage to the ocular surface, hyperosmolarity and tear film instability will help drive a self-propagating vicious cycle once it is initiated. So far, improvement of IL-1Ra (Piyacomn et al., 2019), IL-1 β (D'Souza et al., 2021; Gao et al., 2019), IL-2 (Li, Liu, et al., 2021), IL-4 (Choi et al., 2019), IL-6 (Choi et al., 2019; Li, Liu, et al., 2021; Liu et al., 2017), IL-10 (Choi et al., 2019), IL-17A (Choi et al., 2019; Gao et al., 2019; Liu et al., 2017), IL-17F (D'Souza et al., 2021), IL-18 (D'Souza et al., 2021), MMP-9 (Chung, Han, et al., 2022; D'Souza et al., 2021; Han et al., 2022; Lee et al., 2021), PG-E2 (Liu et al., 2017), TNF- α (Choi et al., 2019; Li, Liu, et al., 2021), IFN- γ (Li, wLiu, et al., 2021), CXCL1 (Li, Liu, et al., 2021), CCL11 (Li, Liu, et al., 2021), TIMP-1 (Li, Liu, et al., 2021), and ocular B cell concentration (D'Souza et al., 2021) after IPL have been reported. Still, no differences in IL-6 (Piyacomn et al., 2019), TGF- β 1, 2, or 3 have been described (Sagaser et al., 2021). Correlations with clinical signs have been found regarding IL-6, TNF- α and ME (Choi et al., 2019); TNF- α , IFN- γ , IL-2, TIMP-1 and TBUT (Li, Liu, et al., 2021); CXCL1, CCL11, TNF- α , IFN- γ , IL-2, IL-6, TIMP-1 and MGs yielding secretion score (Li, Liu, et al., 2021); IL-6 and MGs yielding clear secretion (Liu et al., 2017); and PG-E2 and corneal fluorescein staining (Liu et al., 2017), thus indicating an inflammatory component of DED that might be counteracted through IPL. Whether the improvement of these inflammatory parameters is a result of the direct effect of IPL, improved tear film stability, removal of telangiectatic vessels, a combination of these, or a yet undiscovered factor, is in need of further research and elucidation. Moreover, prospective, randomised studies comparing treatment effects of IPL and established anti-inflammatory treatments are warranted.
- Eradication of *Demodex*: *Demodex* is a parasitic mite species that infects mammals. Only *Demodex folliculorum* and *Demodex brevis* take human hosts. The former is most commonly found in eyelash follicles, while the latter colonises the MGs (English & Nutting, 1981). Ocular *Demodex* infestation plays an etiological role in blepharitis and MGD through blockage of follicles and glands, secretion of inflammatory substances and its symbiotic relationship with *Bacillus olerinus* (Giannaccare et al., 2019; Huo et al., 2021). Chromophores in the exoskeleton of *Demodex* make them theoretically susceptible to coagulation and necrosis following IPL exposure (Cote et al., 2020; Giannaccare et al., 2019), an event documented in real time under video microscopy (Fishman et al., 2020). The clinical effectiveness of IPL in eradicating *Demodex* spp. is still in need of further research. The articles included in this review report eradication rates of 27%, 83% and 100%, respectively (Cheng et al., 2019; Huo et al., 2021; Zhang et al., 2019).
- Antibacterial effect: previous reports have indicated an increased bacterial load and an altered microbiome among DED patients (Graham et al., 2007). The use of topical and systemic antibiotics, often over a long period, to exploit their antimicrobial and anti-inflammatory effects for treating DED is well established (Jones et al., 2017). Long-term use of antibiotics, though, runs the risk of several unpleasant side effects as well as the development of antibiotic resistance. Among the studies included herein, an inhibitory effect of IPL has been found on *Corynebacterium macginleyi* (Xue et al., 2020), as well as *Actinomyces*, *Butyrivococcus*, *Brevibacterium*, *Corynebacterium*, *Clostridium*, *Klebsiella*, *Lactobacillus*, *Neisseria*, and *Streptococcus* (Sagaser et al., 2021).
- Differences were found in the IPL+MGX and MGX study arms without inter-group differences. Whether the antibacterial effect resulted from MGX or the tobramycin and dexamethasone eyedrops prescribed patients following treatment sessions, remains unknown. The third included study evaluating this issue found no significant effect of IPL on ocular bacterial load (Albietz & Schmid, 2018). The role of microbiota in DED and the potential impact of IPL upon it needs further research. Furthermore, prospective, randomised studies are required to compare the effect of established antibiotic treatments and IPL.
- Effect on MG structure: interestingly, several studies have demonstrated a positive effect on the macro- and microstructure of MGs from IPL treatment. Yin et al. found 4%–5% decreased MG dropout following IPL, but this was also the case in the control group treated with eyelid hygiene (Yin et al., 2018). Importantly, though, the cohort treated with IPL demonstrated improved microstructure of MGs as visualised through IVCN, possibly due to photomodulation stimulating acinar cell activity. Cheng et al. later reported similar results, with a 6% decrease in MG dropout and improvement of all IVCN parameters following IPL (Cheng et al., 2019). A reduction in MG dropout was also reported by Huo et al. (2021). These results, however, are not ubiquitous; Xue et al. found no treatment effect on either macro- or microstructure (Xue et al., 2020). It has previously been hypothesised that mechanical stimulation of MG stem cells could be involved in reducing MG dropout (Maskin & Testa, 2018). The location and migration of MG stem cells remain incompletely understood. One possibility is the presence of low turnover stem cells between the acinus and the ductules undergoing asymmetric cell division with the more differentiated daughter cells migrating to the MG acinus (Dietrich et al., 2021). Whether IPL can activate stem cells responsible for MGs residing in the eyelid is an intriguing question that requires further elucidation and studies.
- Other theories concerning the mechanism of action of IPL exist. These include upregulation of mitochondrial adenosine triphosphate production, modulation of redox properties and transcription

factors through photomodulation of cytochrome C oxidase (Mejia et al., 2019), restoration of the physiologic state of relative hypoxia surrounding the MGs (Craig et al., 2015; Knop et al., 2011; Liu et al., 2019), and restoration of MG activity through stimulation of parasympathetic nerves (Liu et al., 2020). A recent animal study employing histologic analysis and transmission electron microscopy reported improved morphology of MGs, improved quality of glandular lipids, downregulation of apoptosis and oxidative stress, and improved structure of mitochondria in the MGs of mice treated with IPL (Xie et al., 2022). These are all areas of interest with gaps in our current understanding that are, consequently, in need of further research.

As the mechanism(s) of action remains shrouded, inclusion of lipidomic and proteomic data would be of great value. Large studies that include these 'omics' generate vast amounts of data, making them ideal for analyses using artificial intelligence. Analysis through supervised and unsupervised machine learning algorithms might help discover novel connections in underlying disease mechanisms and treatment-related effects. Moreover, given that several studies have indicated improved micro- and macroscopic morphology of the MGs following treatment, more extensive, prospective studies employing machine learning algorithms for image analysis are required.

Several new studies have been published over the last few years, and there has been an increase in prospective, randomised single- and double-blinded studies. Among the 79 included articles, 25 are randomised. There are some difficulties in comparing the included studies resulting from the heterogeneity of study design, data collection, questionnaires used, and clinical tests performed. In addition, there are several discrepancies in the number of treatment sessions, treatment intervals, and concurrent treatments such as warm compresses, MGX, topical anti-inflammatories and artificial tears. There are currently no treatment guidelines regarding the number of treatment sessions or the intervals between them. Therefore, there is a demand for further studies to reveal the most suitable settings. These are likely to vary between the various stages and subgroups of DED.

6 | CONCLUSION

There is considerable evidence that IPL treatment is a safe procedure that frequently improves dry eye symptoms and several clinical parameters, especially tear film stability and meibum characteristics. Based on the current literature, the combination of IPL with MGX seems the most efficacious. Although several theories concerning the mechanism of action exist, none of these are complete. The gaps in our understanding remain plentiful, including optimal treatment protocol, treatment area, duration of treatment effect and need for repeated treatment sessions. There is a need for larger, prospective, randomised studies that include biochemical and image analyses, preferably employing machine learning

algorithms to advance our understanding of the mechanisms of actions and thereby further optimise the treatment protocol.

CONFLICT OF INTEREST STATEMENT

Fredrik Fineide: co-owner of The Norwegian dry eye clinic and the Clinic of eye health, Oslo, Norway. Ayyad Z. Khan: co-owner of The Norwegian dry eye clinic and the Clinic of eye health, Oslo, Norway. Jelle Vehof has received financial support for consultancy (mostly speaker fees) from the following companies: Alcon, Santen, Thea Pharma, Horus Pharma and Tramedico. Tor Paaske Utheim: Irrespective of potential conflict of interest, for the sake of transparency, Utheim is co-founder and co-owner of The Norwegian dry eye clinic and the Clinic of eye health, Oslo, Norway, which delivers talks for and/or receives financial support from the following: ABIGO, Alcon, Allergan, AMWO, Bausch&Lomb, Bayer, European school for advanced studies in ophthalmology, InnZ Medical, Medilens Nordic, Medistim, Novartis, Santen, Specsavers, Shire Pharmaceuticals and Thea Laboratories. He has served on the global scientific advisory board for Novartis and Alcon as well as the European advisory board for Shire Pharmaceuticals. Utheim is the Norwegian Global Ambassador for Tear Film and Ocular Surface Society (TFOS), a Board Member of the International Ocular Surface Society, a Consultant at the Norwegian Association for the Blind and Partially Sighted, and the Editor-in-Chief of *Oftalmolog*, an eye journal distributed to all eye doctors in the Nordic region since 1980. Xiangjun Chen: nothing to declare. Morten S. Magnø: nothing to declare.

ORCID

Fredrik Fineide  <https://orcid.org/0000-0003-3835-8772>

Morten S. Magnø  <https://orcid.org/0000-0002-2276-1770>

Xiangjun Chen  <https://orcid.org/0000-0003-0331-9028>

Jelle Vehof  <https://orcid.org/0000-0003-2804-7399>

REFERENCES

- Ahmed, S.A., Taher, I.M.E., Ghoneim, D.F. & Safwat, A.E.M. (2019) Effect of intense pulsed light therapy on tear proteins and lipids in meibomian gland dysfunction. *Journal of Ophthalmic & Vision Research*, 14, 3–10.
- Albietz, J.M. & Schmid, K.L. (2018) Intense pulsed light treatment and meibomian gland expression for moderate to advanced meibomian gland dysfunction. *Clinical & Experimental Optometry*, 101, 23–33.
- Anderson, R.R. & Parrish, J.A. (1983) Selective photothermolysis: precise microsurgery by selective absorption of pulsed radiation. *Science*, 220, 524–527.
- Arita, R., Fukuoka, S. & Kawashima, M. (2020) Proposed algorithm for management of meibomian gland dysfunction based on noninvasive meibography. *Journal of Clinical Medicine*, 10, 65.
- Arita, R., Fukuoka, S., Mizoguchi, T. & Morishige, N. (2020) Multicenter study of intense pulsed light for patients with refractory aqueous-deficient dry eye accompanied by mild meibomian gland dysfunction. *Journal of Clinical Medicine*, 9, 3467. <https://doi.org/10.3390/jcm9113467>
- Arita, R., Fukuoka, S. & Morishige, N. (2019) Therapeutic efficacy of intense pulsed light in patients with refractory meibomian gland dysfunction. *The Ocular Surface*, 17, 104–110.

- Arita, R., Mizoguchi, T., Fukuoka, S. & Morishige, N. (2018) Multicenter study of intense pulsed light therapy for patients with refractory meibomian gland dysfunction. *Cornea*, 37, 1566–1571.
- Ash, C., Town, G., Whittall, R., Tooze, L. & Phillips, J. (2017) Lasers and intense pulsed light (IPL) association with cancerous lesions. *Lasers in Medical Science*, 32, 1927–1933.
- Babilas, P., Schreml, S., Szeimies, R.M. & Landthaler, M. (2010) Intense pulsed light (IPL): a review. *Lasers in Surgery and Medicine*, 42, 93–104.
- Borchman, D., Foulks, G.N., Yappert, M.C., Bell, J., Wells, E., Neravetla, S. et al. (2011) Human meibum lipid conformation and thermodynamic changes with meibomian-gland dysfunction. *Investigative Ophthalmology & Visual Science*, 52, 3805–3817.
- Borchman, D., Foulks, G.N., Yappert, M.C. & Milliner, S.E. (2012) Differences in human meibum lipid composition with meibomian gland dysfunction using NMR and principal component analysis. *Investigative Ophthalmology & Visual Science*, 53, 337–347.
- Bron, A.J., de Paiva, C.S., Chauhan, S.K., Bonini, S., Gabison, E.E., Jain, S. et al. (2017) TFOS DEWS II pathophysiology report. *The Ocular Surface*, 15, 438–510.
- Caravaca, A., Del Barrio, J.L.A., Hergueta, M.C.M. & Amesty, M.A. (2022) Intense pulsed light combined with meibomian gland expression for chalazion management. *Archivos de la Sociedad Española de Oftalmología (English Edition)*, 97(9), 490–496.
- Chen, C., Chen, D., Chou, Y.Y. & Long, Q. (2021) Factors influencing the clinical outcomes of intense pulsed light for meibomian gland dysfunction. *Medicine (Baltimore)*, 100, e28166.
- Chen, Y., Li, J., Wu, Y., Lin, X., Deng, X. & Yun, E.Z. (2021) Comparative evaluation in intense pulsed light therapy combined with or without meibomian gland expression for the treatment of meibomian gland dysfunction. *Current Eye Research*, 46, 1125–1131.
- Cheng, S.N., Jiang, F.G., Chen, H., Gao, H. & Huang, Y.K. (2019) Intense pulsed light therapy for patients with meibomian gland dysfunction and ocular *Demodex* infestation. *Current Medical Science*, 39, 800–809.
- Choi, M., Han, S.J., Ji, Y.W., Choi, Y.J., Jun, I., Alotaibi, M.H. et al. (2019) Meibum Expressibility improvement as a therapeutic target of intense pulsed light treatment in meibomian gland dysfunction and its association with tear inflammatory cytokines. *Scientific Reports*, 9, 7648.
- Chung, H.S., Han, Y.E., Lee, H., Kim, J.Y. & Tchah, H. (2022) Intense pulsed light treatment of the upper and lower eyelids in patients with moderate-to-severe meibomian gland dysfunction. *International Ophthalmology*, 43, 73–82.
- Chung, H.S., Rhim, J.W. & Park, J.H. (2022) Combination treatment with intense pulsed light, thermal pulsation (LipiFlow), and meibomian gland expression for refractory meibomian gland dysfunction. *International Ophthalmology*, 42, 3311–3319.
- Cote, S., Zhang, A.C., Ahmadzai, V., Maleken, A., Li, C., Oppedisano, J. et al. (2020) Intense pulsed light (IPL) therapy for the treatment of meibomian gland dysfunction. *Cochrane Database of Systematic Reviews*, 3, CD013559.
- Craig, J.P., Chen, Y.H. & Turnbull, P.R. (2015) Prospective trial of intense pulsed light for the treatment of meibomian gland dysfunction. *Investigative Ophthalmology & Visual Science*, 56, 1965–1970.
- Craig, J.P., Nichols, K.K., Akpek, E.K., Caffery, B., Dua, H.S., Joo, C.K. et al. (2017) TFOS DEWS II definition and classification report. *The Ocular Surface*, 15, 276–283.
- Dell, S.J., Gaster, R.N., Barbarino, S.C. & Cunningham, D.N. (2017) Prospective evaluation of intense pulsed light and meibomian gland expression efficacy on relieving signs and symptoms of dry eye disease due to meibomian gland dysfunction. *Clinical Ophthalmology*, 11, 817–827.
- di Marino, M., Conigliaro, P., Aiello, F., Valeri, C., Giannini, C., Mancino, R. et al. (2021) Combined low-level light therapy and intense pulsed light therapy for the treatment of dry eye in patients with Sjogren's syndrome. *Journal of Ophthalmology*, 2021, 2023246.
- Dietrich, J., Garreis, F. & Paulsen, F. (2021) Pathophysiology of meibomian glands - an overview. *Ocular Immunology and Inflammation*, 29, 803–810.
- D'Souza, S., Padmanabhan Nair, A., Iyappan, G., Dickman, M.M., Thakur, P., Mullick, R. et al. (2022) Clinical and molecular outcomes after combined intense pulsed light therapy with low-level light therapy in recalcitrant evaporative dry eye disease with meibomian gland dysfunction. *Cornea*, 41(9), 1080–1087.
- English, F.P. & Nutting, W.B. (1981) Demodocosis of ophthalmic concern. *American Journal of Ophthalmology*, 91, 362–372.
- Fan, Q., Pazo, E.E., You, Y., Zhang, C., Zhang, C., Xu, L. et al. (2020) Subjective quality of vision in evaporative dry eye patients after intense pulsed light. *Photobiomodulation, Photomedicine, and Laser Surgery*, 38, 444–451.
- Fishman, H.A., Periman, L.M. & Shah, A.A. (2020) Real-time video microscopy of in vitro *Demodex* death by intense pulsed light. *Photobiomodulation, Photomedicine, and Laser Surgery*, 38, 472–476.
- Foulks, G.N., Borchman, D., Yappert, M., Kim, S.H. & McKay, J.W. (2010) Topical azithromycin therapy for meibomian gland dysfunction: clinical response and lipid alterations. *Cornea*, 29, 781–788.
- Gao, Y.F., Liu, R.J., Li, Y.X., Huang, C., Liu, Y.Y., Hu, C.X. et al. (2019) Comparison of anti-inflammatory effects of intense pulsed light with tobramycin/dexamethasone plus warm compress on dry eye associated meibomian gland dysfunction. *International Journal of Ophthalmology*, 12, 1708–1713.
- Giannaccare, G., Taroni, L., Senni, C. & Scorgia, V. (2019) Intense pulsed light therapy in the treatment of meibomian gland dysfunction: current perspectives. *Clinical Optometry*, 11, 113–126.
- Goldman, M.P. (1997) Treatment of benign vascular lesions with the Photoderm VL high-intensity pulsed light source. *Advances in Dermatology*, 13, 503–521.
- Graham, J.E., Moore, J.E., Jiru, X., Moore, J.E., Goodall, E.A., Dooley, J.S. et al. (2007) Ocular pathogen or commensal: a PCR-based study of surface bacterial flora in normal and dry eyes. *Investigative Ophthalmology & Visual Science*, 48, 5616–5623.
- Guilloto Caballero, S., Garcia Madrona, J.L. & Colmenero Reina, E. (2017) Effect of pulsed laser light in patients with dry eye syndrome. *Archivos de la Sociedad Española de Oftalmología*, 92, 509–515.
- Gupta, P.K., Vora, G.K., Matossian, C., Kim, M. & Stinnett, S. (2016) Outcomes of intense pulsed light therapy for treatment of evaporative dry eye disease. *Canadian Journal of Ophthalmology*, 51, 249–253.
- Han, J.Y., Lee, Y., Nam, S., Moon, S.Y., Lee, H., Kim, J.Y. et al. (2022) Effect of intense pulsed light using acne filter on eyelid margin telangiectasia in moderate-to-severe meibomian gland dysfunction. *Lasers in Medical Science*, 37, 2185–2192.
- Huang, X., Qin, Q., Wang, L., Zheng, J., Lin, L. & Jin, X. (2019) Clinical results of intraductal meibomian gland probing combined with intense pulsed light in treating patients with refractory obstructive meibomian gland dysfunction: a randomized controlled trial. *BMC Ophthalmology*, 19, 211.
- Huo, Y., Mo, Y., Wu, Y., Fang, F. & Jin, X. (2021) Therapeutic effect of intense pulsed light with optimal pulse technology on meibomian gland dysfunction with and without ocular *Demodex* infestation. *Annals of Translational Medicine*, 9, 238.
- Huo, Y., Wan, Q., Hou, X., Zhang, Z., Zhao, J., Wu, Z. et al. (2022) Therapeutic effect of intense pulsed light in patients with Sjogren's syndrome related dry eye. *Journal of Clinical Medicine*, 11, 1377.
- Iradier, M.T., del Buey, M.A., Peris-Martinez, C., Cedano, P. & Pinero, D.P. (2021) Characterization and prediction of the clinical outcome of intense pulsed light-based treatment in dry eye associated to meibomian gland dysfunction. *Journal of Clinical Medicine*, 10, 3573.
- Jiang, X., Lv, H., Song, H., Zhang, M., Liu, Y., Hu, X. et al. (2016) Evaluation of the safety and effectiveness of intense pulsed light in the treatment of meibomian gland dysfunction. *Journal of Ophthalmology*, 2016, 1910694–1910698.
- Jones, L., Downie, L.E., Korb, D., Benitez-Del-Castillo, J.M., Dana, R., Deng, S.X. et al. (2017) TFOS DEWS II management and therapy report. *The Ocular Surface*, 15, 575–628.
- Karaca, E.E., Evren Kemer, O. & Ozek, D. (2018) Intense regulated pulse light for the meibomian gland dysfunction. *European Journal of Ophthalmology*, 30(2), 289–292.

- Kim, M. & Min, J. (2022) Effect of intense pulsed-light treatment using a novel dual-band filter in patients with meibomian gland dysfunction. *Journal of Clinical Medicine*, 11, 3607.
- Knop, E., Knop, N., Millar, T., Obata, H. & Sullivan, D.A. (2011) The international workshop on meibomian gland dysfunction: report of the subcommittee on anatomy, physiology, and pathophysiology of the meibomian gland. *Investigative Ophthalmology & Visual Science*, 52, 1938–1978.
- Lee, H., Han, Y.E., Park, S.Y., Lee, J.H., Chung, H.S., Moon, S.Y. et al. (2021) Changes in the expression of matrix metalloproteinase-9 after intense pulsed light therapy combined with meibomian gland expression in moderate and severe meibomian gland dysfunction. *Contact Lens & Anterior Eye*, 44, 101339.
- Li, D., Lin, S.B. & Cheng, B. (2019) Intense pulsed light treatment for meibomian gland dysfunction in skin types III/IV. *Photobiomodulation, Photomedicine, and Laser Surgery*, 37, 70–76.
- Li, D., Lin, S.B., Cheng, L.H., Zhang, M.Z. & Cheng, B. (2021) Intense pulsed light treatment for itch associated with allergic Keratoconjunctivitis: a retrospective study of 35 cases. *Photobiomodulation, Photomedicine, and Laser Surgery*, 39, 196–203.
- Li, D., Lin, S.B., Zhang, M.Z. & Cheng, B. (2020) Preliminary assessment of intense pulsed light treatment on the upper eyelids for meibomian gland dysfunction. *Photobiomodulation, Photomedicine, and Laser Surgery*, 38, 249–254.
- Li, Q., Liu, J., Liu, C., Piao, J., Yang, W., An, N. et al. (2021) Effects of intense pulsed light treatment on tear cytokines and clinical outcomes in meibomian gland dysfunction. *PLoS One*, 16, e0256533.
- Liu, R., Rong, B., Tu, P., Tang, Y., Song, W., Toyos, R. et al. (2017) Analysis of cytokine levels in tears and clinical correlations after intense pulsed light treating meibomian gland dysfunction. *American Journal of Ophthalmology*, 183, 81–90.
- Liu, S., Tang, S., Dong, H. & Huang, X. (2020) Intense pulsed light for the treatment of meibomian gland dysfunction: a systematic review and meta-analysis. *Experimental and Therapeutic Medicine*, 20, 1815–1821.
- Liu, Y., Chen, D., Chen, X., Kam, W.R., Hatton, M.P. & Sullivan, D.A. (2019) Hypoxia: a breath of fresh air for the meibomian gland. *The Ocular Surface*, 17, 310–317.
- Markoulli, M., Chandramohan, N. & Papas, E.B. (2021) Photobiomodulation (low-level light therapy) and dry eye disease. *Clinical & Experimental Optometry*, 104, 561–566.
- Marta, A., Baptista, P.M., Heitor Marques, J., Almeida, D., Jose, D., Sousa, P. et al. (2021) Intense pulsed plus low-level light therapy in meibomian gland dysfunction. *Clinical Ophthalmology*, 15, 2803–2811.
- Martinez-de-la-Casa, J.M., Oribio-Quinto, C., Milans-Del-Bosch, A., Perez-Garcia, P., Morales-Fernandez, L., Garcia-Bella, J. et al. (2022) Intense pulsed light-based treatment for the improvement of symptoms in glaucoma patients treated with hypotensive eye drops. *Eye and Vision*, 9, 12.
- Maskin, S.L. & Testa, W.R. (2018) Growth of meibomian gland tissue after intraductal meibomian gland probing in patients with obstructive meibomian gland dysfunction. *The British Journal of Ophthalmology*, 102, 59–68.
- Mejia, L.F., Gil, J.C. & Jaramillo, M. (2019) Intense pulsed light therapy: a promising complementary treatment for dry eye disease. *Archivos de la Sociedad Española de Oftalmología*, 94, 331–336.
- Min, J.S., Yoon, S.H., Kim, K.Y., Jun, I., Kim, E.K., Kim, T.I. et al. (2022) Treatment effect and pain during treatment with intense pulsed-light therapy according to the light guide in patients with meibomian gland dysfunction. *Cornea*, 41, 177–182.
- Mühlbauer, W., Nath, G. & Kreitmair, A. (1976) Treatment of capillary hemangiomas and nevi flammei with light. *Langenbecks Archiv Fur Chirurgie*, 76, 91–94.
- Murtaza, F., Toameh, D., Al-Habib, S., Maini, R., Chiu, H.H., Tam, E.S. et al. (2021) Safety and efficacy of BroadBand intense pulsed light therapy for dry eye disease with meibomian gland dysfunction. *Clinical Ophthalmology*, 15, 3983–3991.
- Nelson, J.D., Craig, J.P., Akpek, E.K., Azar, D.T., Belmonte, C., Bron, A.J. et al. (2017) TFOS DEWS II introduction. *The Ocular Surface*, 15, 269–275.
- Nelson, J.D., Shimazaki, J., Benitez-del-Castillo, J.M., Craig, J.P., McCulley, J.P., Den, S. et al. (2011) The international workshop on meibomian gland dysfunction: report of the definition and classification subcommittee. *Investigative Ophthalmology & Visual Science*, 52, 1930–1937.
- Pazo, E.E., Huang, H., Fan, Q., Zhang, C., Yue, Y., Yang, L. et al. (2021) Intense pulse light for treating post-LASIK refractory dry eye. *Photobiomodulation, Photomedicine, and Laser Surgery*, 39, 155–163.
- Perez-Silguero, M.A., Perez-Silguero, D., Rivero-Santana, A., Bernal-Blasco, M.I. & Encinas-Pisa, P. (2021) Combined intense pulsed light and low-level light therapy for the treatment of dry eye: a retrospective before-after study with one-year follow-up. *Clinical Ophthalmology*, 15, 2133–2140.
- Piyacomn, Y., Kasetsuwan, N., Reinprayoon, U., Satitpitakul, V. & Tesapirat, L. (2020) Efficacy and safety of intense pulsed light in patients with meibomian gland dysfunction—a randomized, double-masked, sham-controlled clinical trial. *Cornea*, 39(3), 325–332.
- Qiao, C., Li, L., Wang, H., Zhao, C., Ke, L., Sen, D. et al. (2021) Adverse events of intense pulsed light combined with meibomian gland expression versus meibomian gland expression in the treatment of meibomian gland dysfunction. *Lasers in Surgery and Medicine*, 53, 664–670.
- Raulin, C., Greve, B. & Grema, H. (2003) IPL technology: a review. *Lasers in Surgery and Medicine*, 32, 78–87.
- Ren, X., Chou, Y., Wang, Y., Chen, Y., Liu, Z. & Li, X. (2021) Comparison of intense pulsed light and near-infrared light in the treatment of dry eye disease: a prospective randomized study. *Acta Ophthalmologica*, 99, e1307–e1314.
- Rong, B., Tang, Y., Liu, R., Tu, P., Qiao, J., Song, W. et al. (2018) Long-term effects of intense pulsed light combined with meibomian gland expression in the treatment of meibomian gland dysfunction. *Photomedicine and Laser Surgery*, 36, 562–567.
- Rong, B., Tang, Y., Tu, P., Liu, R., Qiao, J., Song, W. et al. (2018) Intense pulsed light applied directly on eyelids combined with meibomian gland expression to treat meibomian gland dysfunction. *Photomedicine and Laser Surgery*, 36, 326–332.
- Sagaser, S., Butterfield, R., Kosiorek, H., Kusne, Y., Maldonado, J., Fautsch, M.P. et al. (2021) Effects of intense pulsed light on tear film TGF-beta and microbiome in ocular rosacea with dry eye. *Clinical Ophthalmology*, 15, 323–330.
- Schaumberg, D.A., Nichols, J.J., Papas, E.B., Tong, L., Uchino, M. & Nichols, K.K. (2011) The international workshop on meibomian gland dysfunction: report of the subcommittee on the epidemiology of, and associated risk factors for, MGD. *Investigative Ophthalmology & Visual Science*, 52, 1994–2005.
- Schuh, A., Muth, D., Shajari, M., Mayer, W.J., Priglinger, S. & Messmer, E. (2021) Effect of IPL in patients with meibomian gland dysfunction. *Klinische Monatsblätter für Augenheilkunde*, 238, 893–898.
- Seo, K.Y., Kang, S.M., Ha, D.Y., Chin, H.S. & Jung, J.W. (2018) Long-term effects of intense pulsed light treatment on the ocular surface in patients with rosacea-associated meibomian gland dysfunction. *Contact Lens & Anterior eye*, 41, 430–435.
- Shin, K.Y., Lim, D.H., Moon, C.H., Kim, B.J. & Chung, T.Y. (2021) Intense pulsed light plus meibomian gland expression versus intense pulsed light alone for meibomian gland dysfunction: a randomized crossover study. *PLoS One*, 16, e0246245.
- Solomos, L., Bouthour, W., Malcles, A., Thumann, G. & Massa, H. (2021) Meibomian gland dysfunction. In: *Intense pulsed light therapy in combination with low-level light therapy as rescue treatment*, Vol. 57. Medicina (Kaunas): MDPI medicina.
- Song, Y., Yu, S., He, X., Yang, L., Wu, Y., Qin, G. et al. (2021) Tear film interferometry assessment after intense pulsed light in dry eye disease: a randomized, single masked, sham-controlled study. *Contact Lens & Anterior eye*, 45, 101499.
- Stapleton, F., Alves, M., Bunya, V.Y., Jalbert, I., Lekhanont, K., Malet, F. et al. (2017) TFOS DEWS II epidemiology report. *The Ocular Surface*, 15, 334–365.
- Stonecipher, K., Abell, T.G., Chotiner, B., Chotiner, E. & Potvin, R. (2019) Combined low level light therapy and intense pulsed light therapy for the treatment of meibomian gland dysfunction. *Clinical Ophthalmology*, 13, 993–999.

- Tang, Y., Liu, R., Tu, P., Song, W., Qiao, J., Yan, X. et al. (2021) A retrospective study of treatment outcomes and prognostic factors of intense pulsed light therapy combined with meibomian gland expression in patients with meibomian gland dysfunction. *Eye & Contact Lens*, 47, 38–44.
- Tashbayev, B., Yazdani, M., Arita, R., Fineide, F. & Utheim, T.P. (2020) Intense pulsed light treatment in meibomian gland dysfunction: a concise review. *The Ocular Surface*, 18, 583–594.
- Tomlinson, A., Bron, A.J., Korb, D.R., Amano, S., Paugh, J.R., Pearce, E.I. et al. (2011) The international workshop on meibomian gland dysfunction: report of the diagnosis subcommittee. *Investigative Ophthalmology & Visual Science*, 52, 2006–2049.
- Toyos, R., Desai, N.R., Toyos, M. & Dell, S.J. (2022) Intense pulsed light improves signs and symptoms of dry eye disease due to meibomian gland dysfunction: a randomized controlled study. *PLoS One*, 17, e0270268.
- Toyos, R., McGill, W. & Briscoe, D. (2015) Intense pulsed light treatment for dry eye disease due to meibomian gland dysfunction: a 3-year retrospective study. *Photomedicine and Laser Surgery*, 33, 41–46.
- Toyos, R., Toyos, M., Willcox, J., Mulliniks, H. & Hoover, J. (2019) Evaluation of the safety and efficacy of intense pulsed light treatment with meibomian gland expression of the upper eyelids for dry eye disease. *Photobiomodulation, Photomedicine, and Laser Surgery*, 37, 527–531.
- Uchino, M., Uchino, Y., Dogru, M., Kawashima, M., Yokoi, N., Komuro, A. et al. (2014) Dry eye disease and work productivity loss in visual display users: the Osaka study. *American Journal of Ophthalmology*, 157, 294–300.
- Vegunta, S., Patel, D. & Shen, J.F. (2016) Combination therapy of intense pulsed light therapy and meibomian gland expression (IPL/MGX) can improve dry eye symptoms and meibomian gland function in patients with refractory dry eye: a retrospective analysis. *Cornea*, 35, 318–322.
- Verges, C., Salgado-Borges, J. & Ribot, F.M. (2021) Prospective evaluation of a new intense pulsed light, thermaeye plus, in the treatment of dry eye disease due to meibomian gland dysfunction. *Journal of Optometry*, 14, 103–113.
- Vigo, L., Giannaccare, G., Sebastiani, S., Pellegrini, M. & Carones, F. (2019) Intense pulsed light for the treatment of dry eye owing to meibomian gland dysfunction. *Journal of Visualized Experiments*, 146, e57811.
- Vigo, L., Taroni, L., Bernabei, F., Pellegrini, M., Sebastiani, S., Mercanti, A. et al. (2019) Ocular surface workup in patients with meibomian gland dysfunction treated with intense regulated pulsed light. *Diagnostics (Basel)*, 9, 147.
- Wei, S., Ren, X., Wang, Y., Chou, Y. & Li, X. (2020) Therapeutic effect of intense pulsed light (IPL) combined with meibomian gland expression (MGX) on meibomian gland dysfunction (MGD). *Journal of Ophthalmology*, 2020, 3684963–3684967.
- Weijie, G., Hongmei, L. & Wei, L. (2017) Intense pulsed light therapy. *Photomedicine: Advances in Clinical Practice*, 177. <https://doi.org/10.5772/65345>
- Willcox, M.D.P., Argueso, P., Georgiev, G.A., Holopainen, J.M., Laurie, G.W., Millar, T.J. et al. (2017) TFOS DEWS II tear film report. *The Ocular Surface*, 15, 366–403.
- Wu, Y., Li, J., Hu, M., Zhao, Y., Lin, X., Chen, Y. et al. (2020) Comparison of two intense pulsed light patterns for treating patients with meibomian gland dysfunction. *International Ophthalmology*, 40, 1695–1705.
- Wu, Y., Mou, Y., Zhang, Y., Han, Y., Lin, L., Huo, Y. et al. (2022) Efficacy of intense pulsed light combined blood extract eye drops for treatment of nociceptive pain in dry eye patients. *Journal of Clinical Medicine*, 11, 1312.
- Wu, Y., Xu, L., Song, Y., Zhang, Q., Qin, G., Yang, L. et al. (2022) Management of Post-LASIK dry eye with intense pulsed light in combination with 0.1% sodium hyaluronate and heated eye mask. *Ophthalmology and Therapy*, 11, 161–176.
- Xie, L., Song, W., Dong, W., Li, Y., Chen, S., Sun, X. et al. (2022) Indirect application of intense pulsed light induces therapeutic effects on experimental murine meibomian gland dysfunction. *Frontiers in Medicine*, 9, 923280.
- Xu, L., Wu, Y., Song, Y., Zhang, Q., Qin, G., Yang, L. et al. (2022) Comparison between heated eye mask and intense pulsed light treatment for contact lens-related dry eye. *Photobiomodulation, Photomedicine, and Laser Surgery*, 40, 189–197.
- Xue, A.L., Wang, M.T.M., Ormonde, S.E. & Craig, J.P. (2020) Randomised double-masked placebo-controlled trial of the cumulative treatment efficacy profile of intense pulsed light therapy for meibomian gland dysfunction. *The Ocular Surface*, 18, 286–297.
- Yan, S. & Wu, Y. (2021) Efficacy and safety of intense pulsed light therapy for dry eye caused by meibomian gland dysfunction: a randomised trial. *Ann Palliat Med*, 10, 7857–7865.
- Yan, X., Hong, J., Jin, X., Chen, W., Rong, B., Feng, Y. et al. (2021) The efficacy of intense pulsed light combined with meibomian gland expression for the treatment of dry eye disease due to meibomian gland dysfunction: a multicenter, randomized controlled trial. *Eye & Contact Lens*, 47, 45–53.
- Yang, L., Pazo, E.E., Qin, G., Zhang, Q., Wu, Y., Song, Y. et al. (2021) Effect of intense pulsed light on anterior corneal aberrations and quality of vision in patients with evaporative dry eye. *Photobiomodulation, Photomedicine, and Laser Surgery*, 39, 185–195.
- Yang, L., Pazo, E.E., Zhang, Q., Wu, Y., Song, Y., Qin, G. et al. (2021) Treatment of contact lens related dry eye with intense pulsed light. *Contact Lens & Anterior eye*, 45, 101449.
- Yin, Y., Liu, N., Gong, L. & Song, N. (2018) Changes in the meibomian gland after exposure to intense pulsed light in meibomian gland dysfunction (MGD) patients. *Current Eye Research*, 43, 308–313.
- Yurttaser Ocak, S., Karakus, S., Ocak, O.B., Cakir, A., Bolukbasi, S., Erden, B. et al. (2020) Intense pulse light therapy treatment for refractory dry eye disease due to meibomian gland dysfunction. *International Ophthalmology*, 40, 1135–1141.
- Zarei-Ghanavati, S., Hassanzadeh, S., Azimi Khorasani, A., Ehsaei, A. & Bakhtiari, E. (2021) Efficacy of five-flash intense pulsed light therapy technique in patients with meibomian gland dysfunction. *Clinical & Experimental Optometry*, 105, 1–7.
- Zarei-Ghanavati, S., Hassanzadeh, S., Khorasani, A.A. & Ehsaei, A. (2021) The effect of meibomian gland dysfunction treatment on sleep quality. *Journal of Current Ophthalmology*, 33, 272–276.
- Zhang, X., Song, N. & Gong, L. (2019) Therapeutic effect of intense pulsed light on ocular Demodicosis. *Current Eye Research*, 44, 250–256.
- Zhang-Nunes, S., Guo, S., Lee, D., Chang, J. & Nguyen, A. (2021) Safety and efficacy of an augmented intense pulse light protocol for dry eye syndrome and blepharitis. *Photobiomodulation, Photomedicine, and Laser Surgery*, 39, 178–184.
- Zhao, H., Wu, S.N., Shao, Y., Xiao, D., Tang, L.Y., Cheng, Z. et al. (2022) Lipidomics profiles revealed alterations in patients with meibomian gland dysfunction after exposure to intense pulsed light. *Frontiers in Neurology*, 13, 827544.

How to cite this article: Fineide, F., Magnø, M.S., Khan, A.Z., Chen, X., Vehof, J. & Utheim, T.P. (2023) Intense pulsed light treatment in meibomian gland dysfunction: Past, present, and future. *Acta Ophthalmologica*, 00, 1–29. Available from: <https://doi.org/10.1111/aos.15759>